Cysts of the jaw

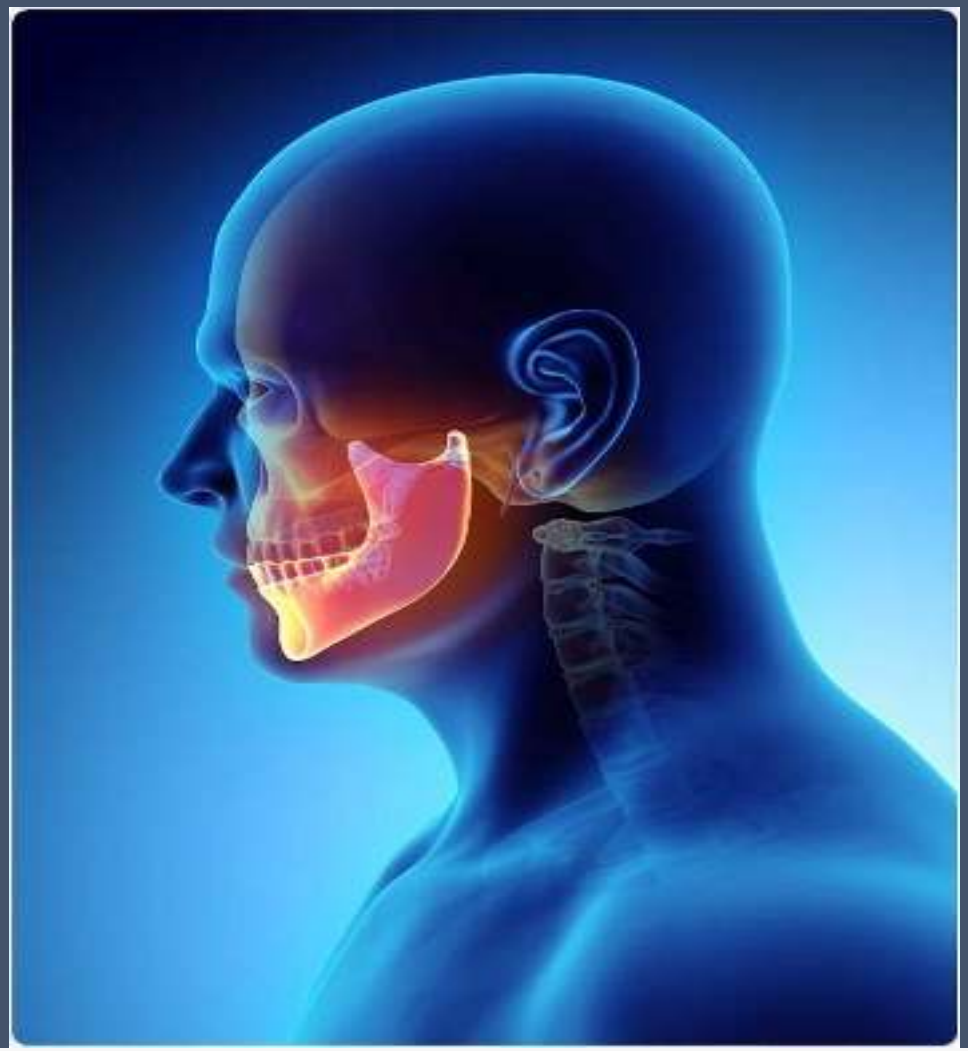

What is a jaw cyst?

cysts

- **Cysts are epithelium-lined pathological cavities, usually filled with fluid, semi-solid material, or cellular debris.**
- **‘a pathological cavity having fluid or semi-fluid contents that has not been created by the accumulation of pus’**

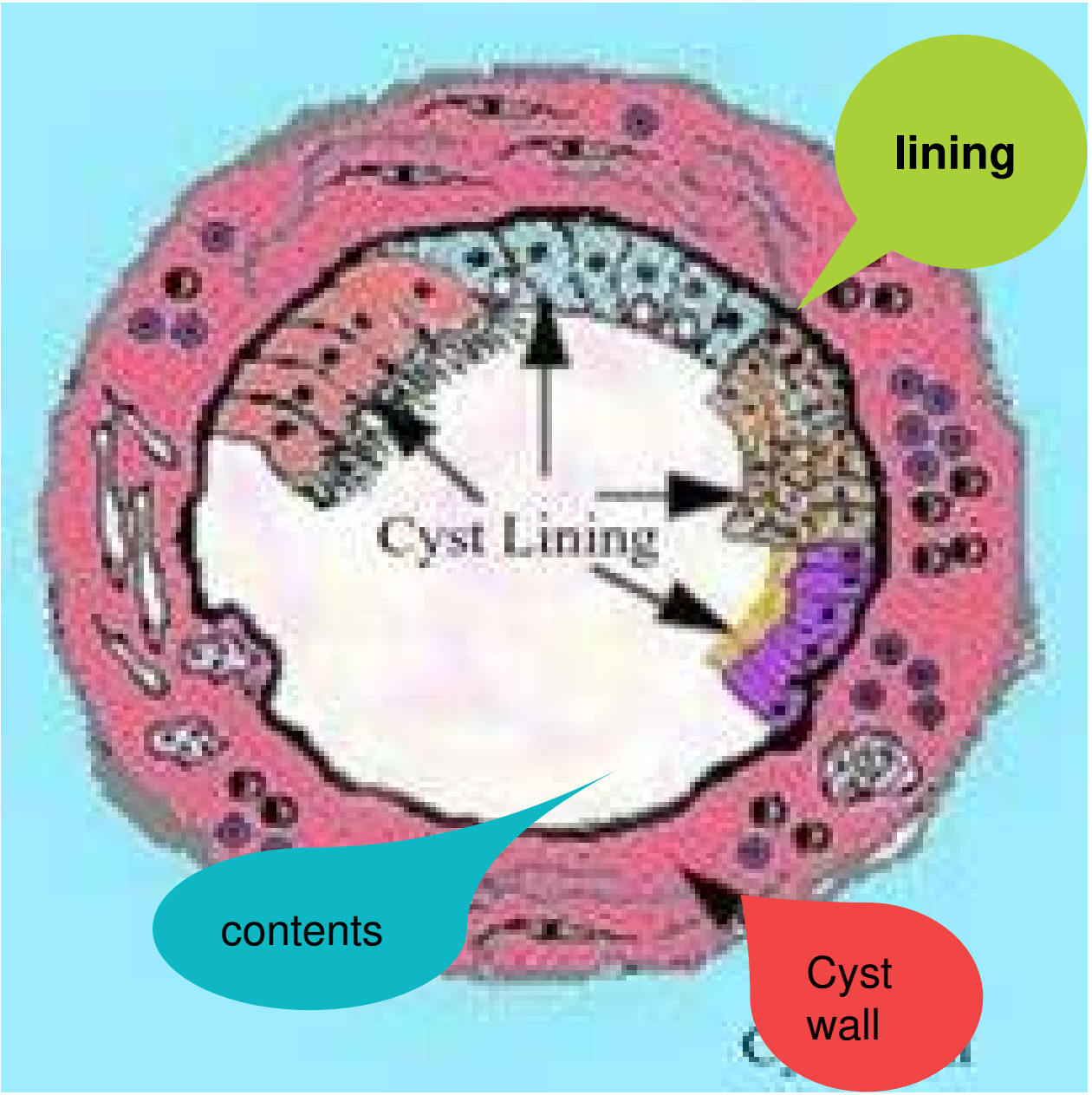

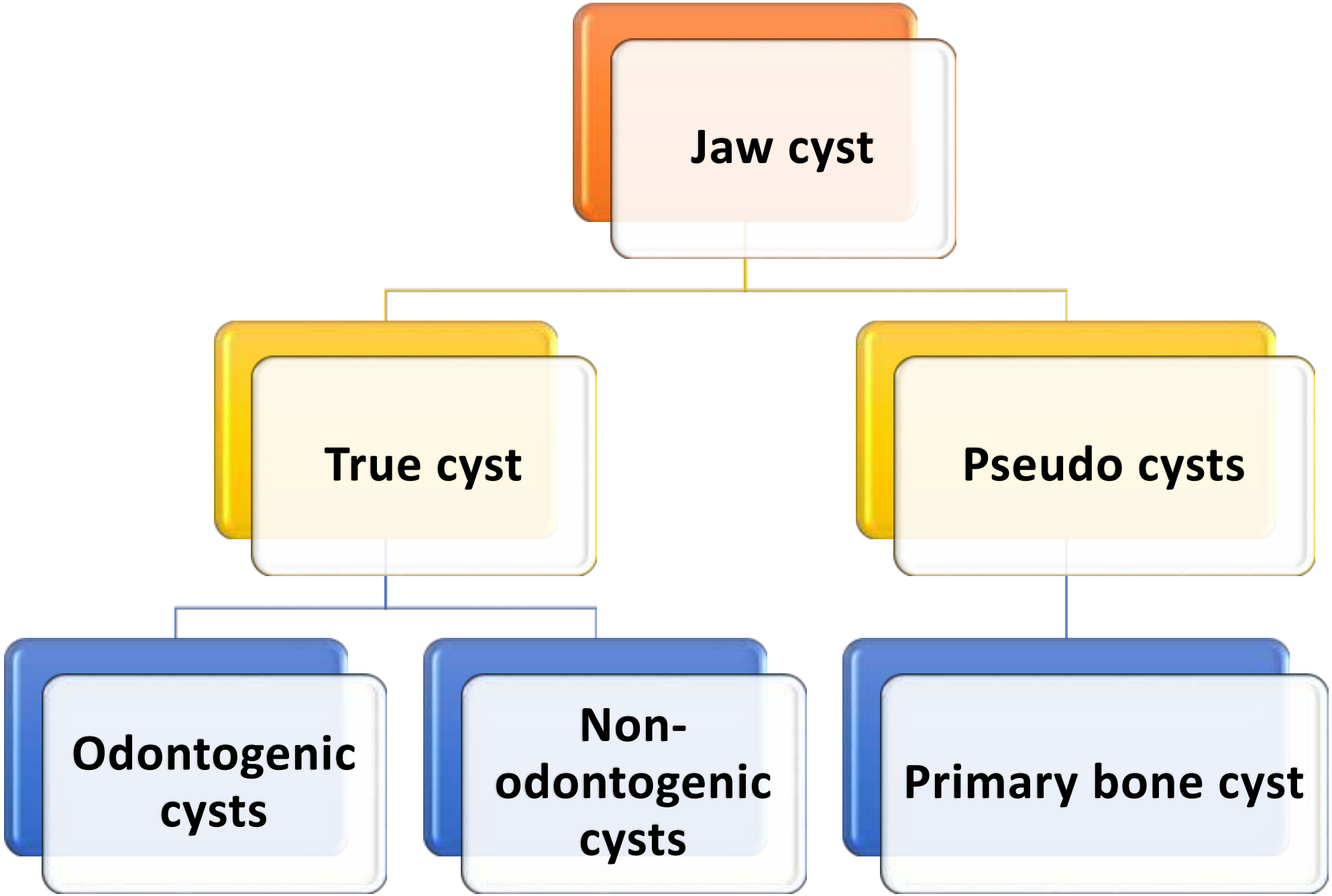
Jaw cyst
True cyst
Pseudo cysts
Odontogenic cysts
Non-odontogenic cysts
Primary bone cyst

I-Non-odontogenic cysts

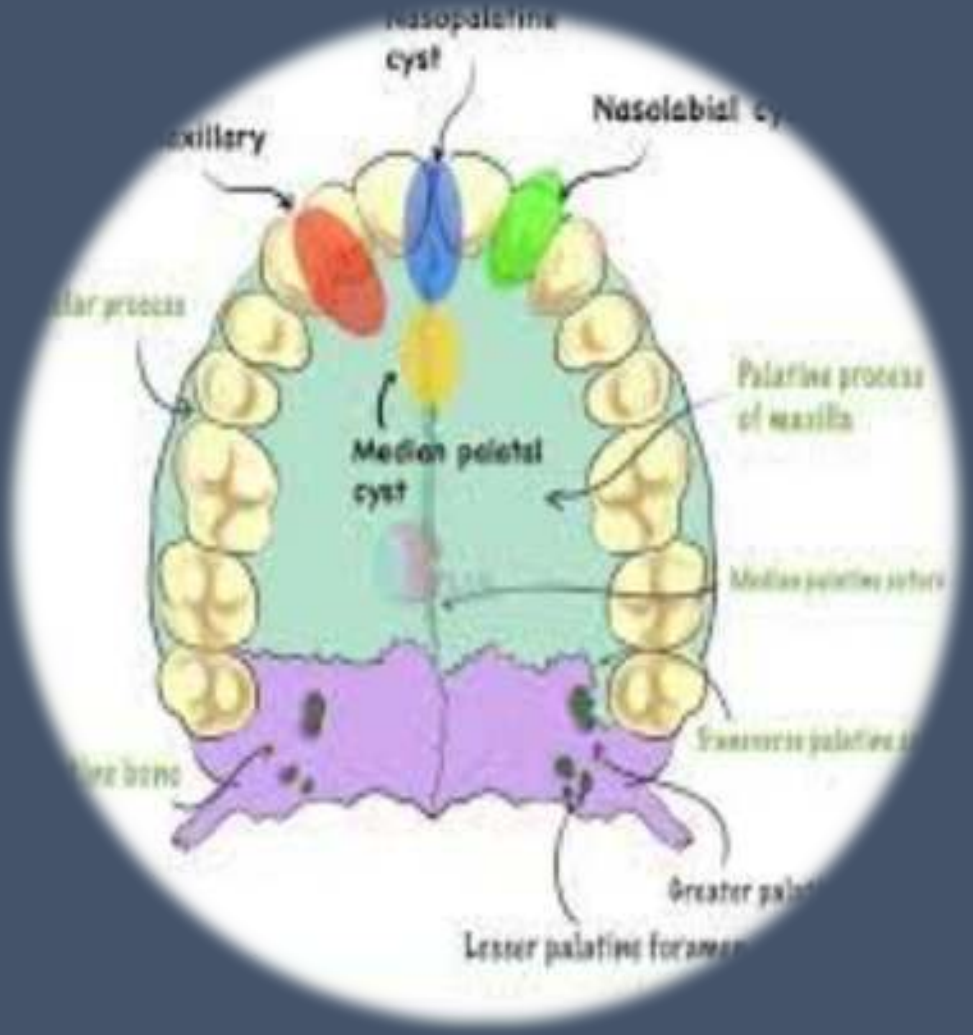

Some of the non-odontogenic cysts have been considered historically as "*fissural*" cysts because they were thought to arise from epithelium entrapped along embryonal lines of fusion.

1- Nasoalveolar(Nasolabial) cyst

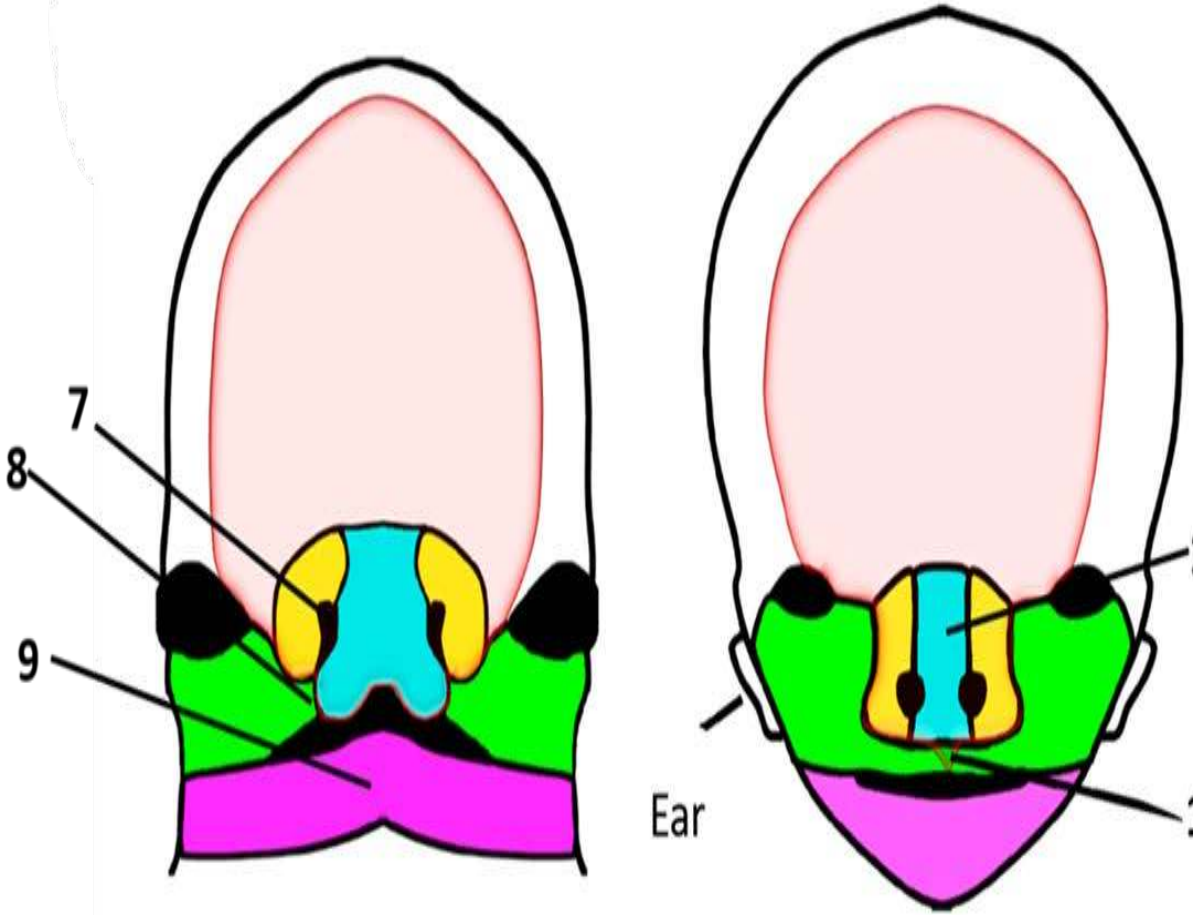

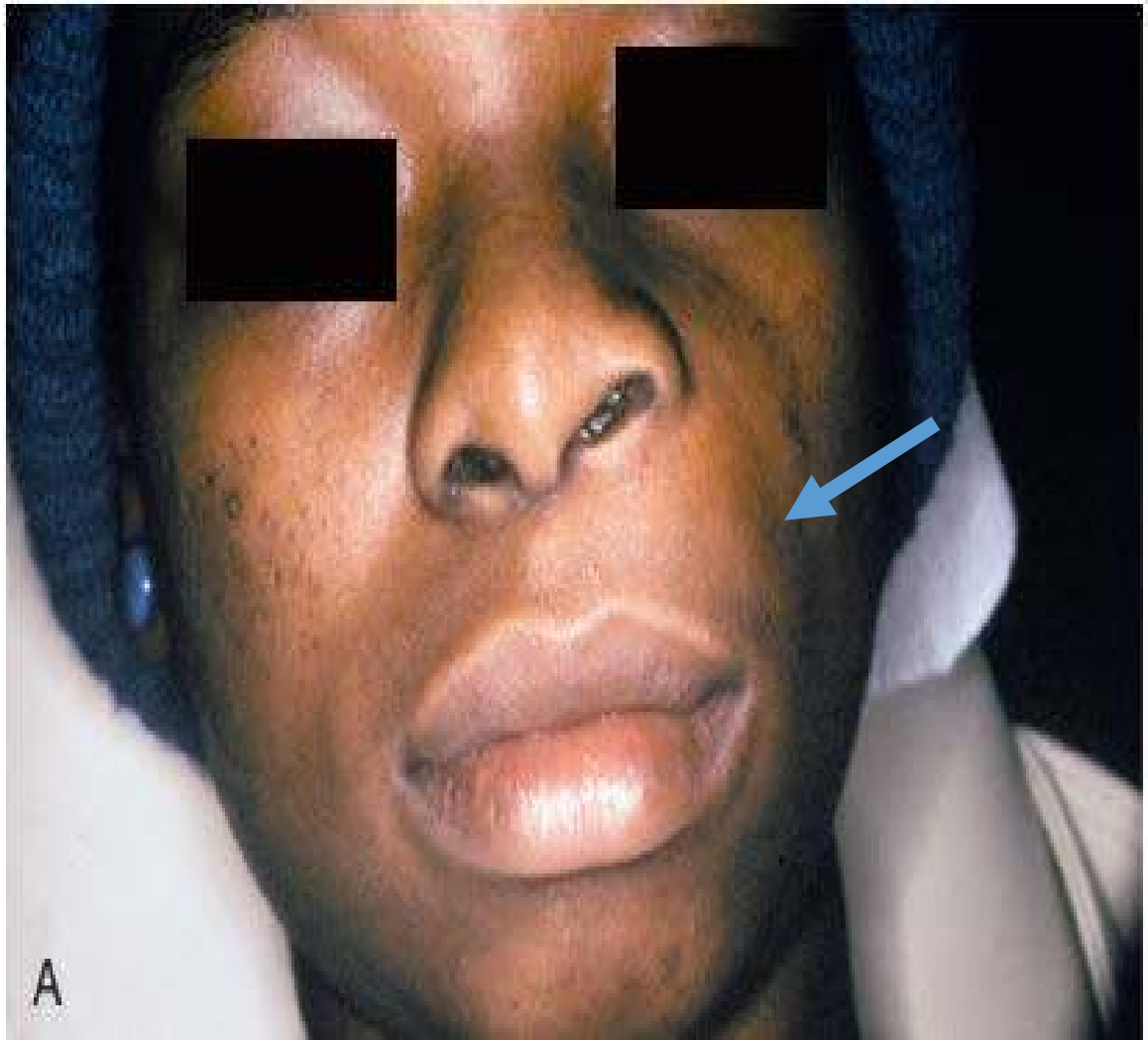

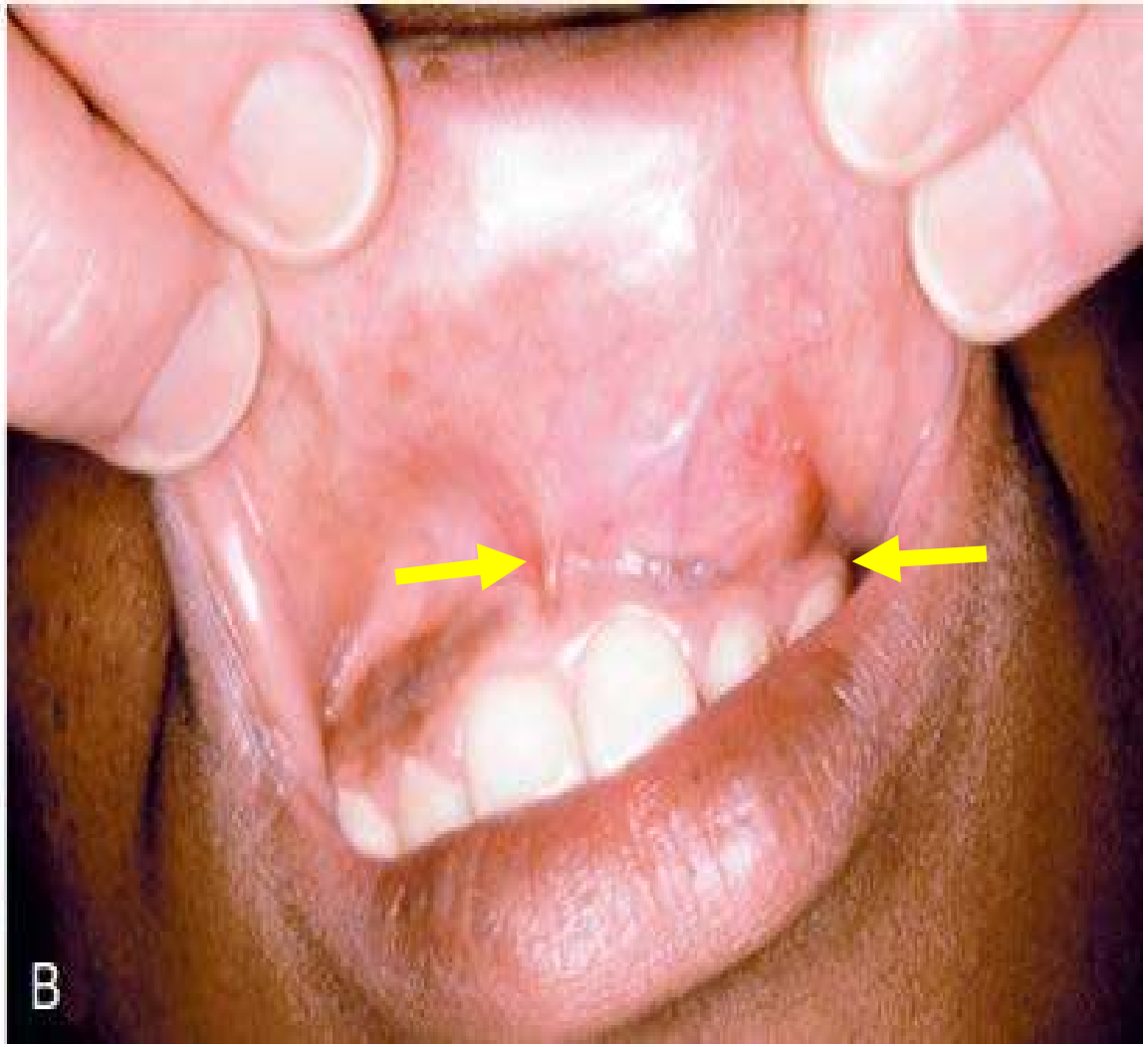

Nasoalveolar(Nasolabial) Cyst.

A, Enlargement of the left upper lip with an elevation of the ala of the nose.

B, Intraoral swelling fills the maxillary labial fold

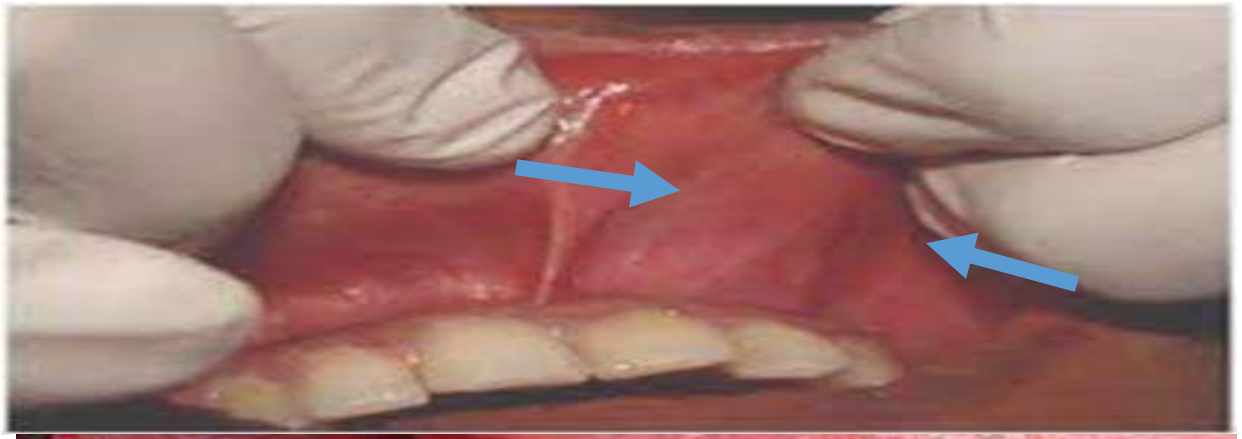

Nasoalveolar (nasolabial) cyst

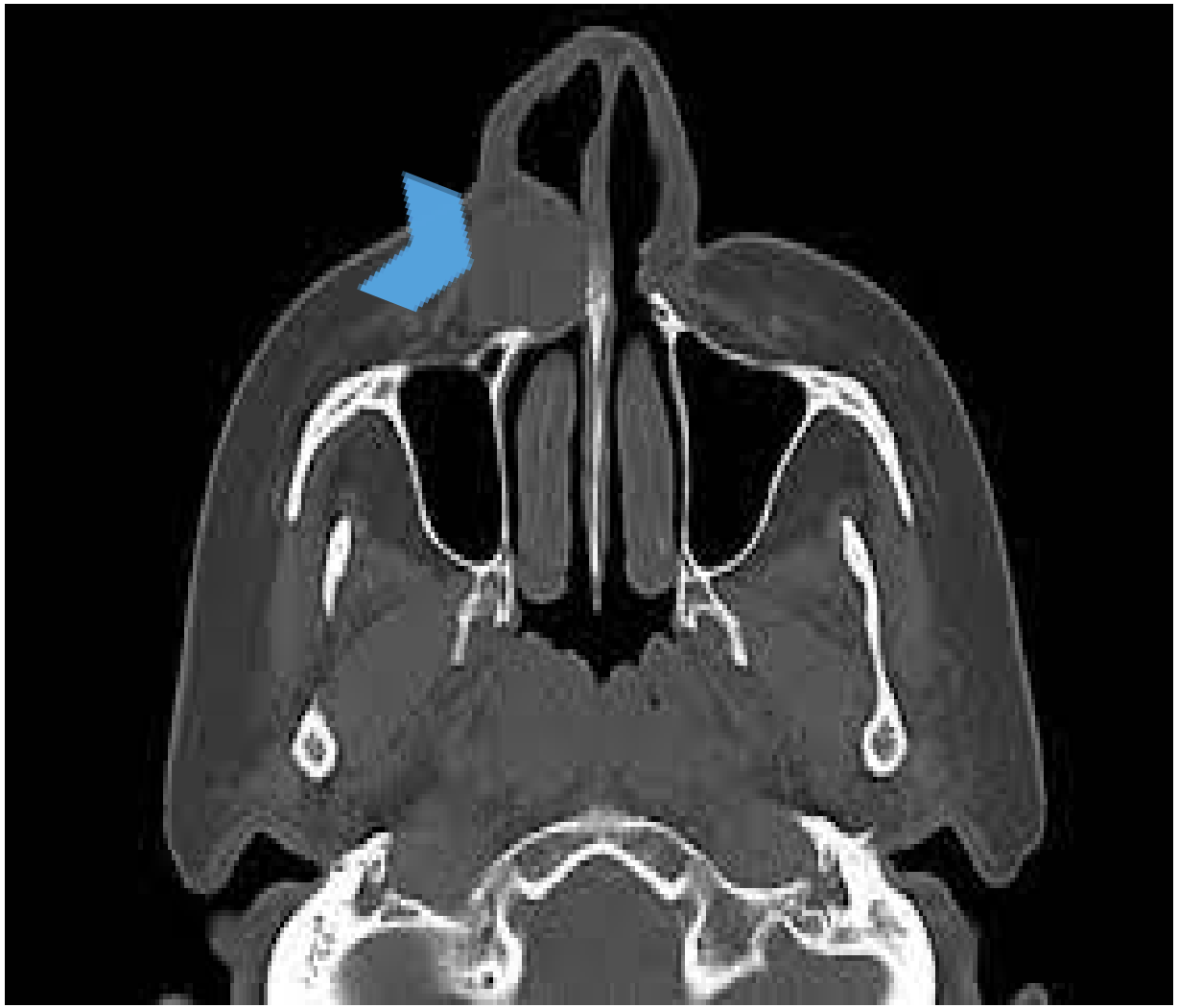

nasolabial cyst (axial CT scan)

Well-defined rounded soft tissue mass at the right alar region with cortical scalloping of the adjacent maxilla

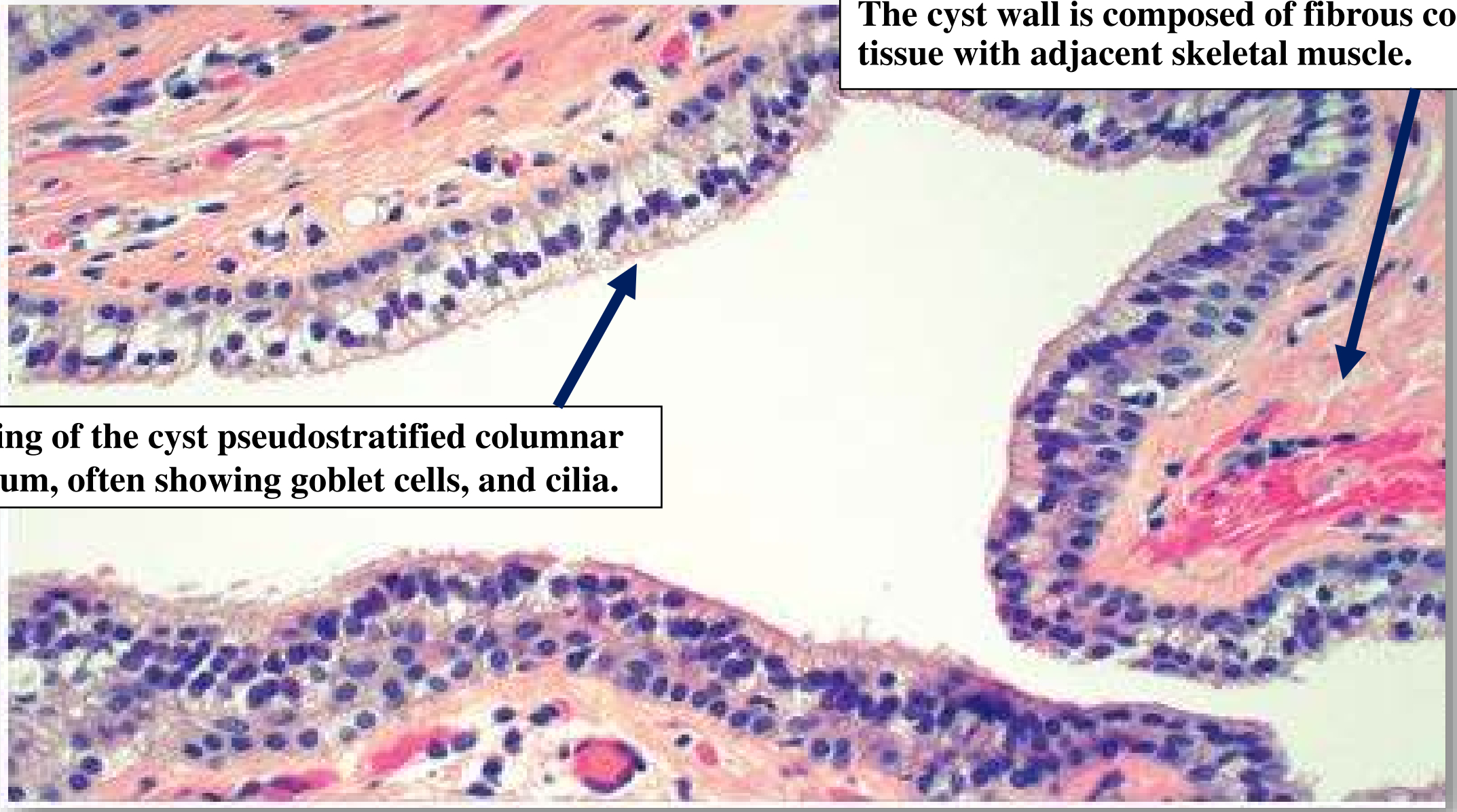

Nasolabial cyst

2- Nasopalatine duct (incisive canal) cyst

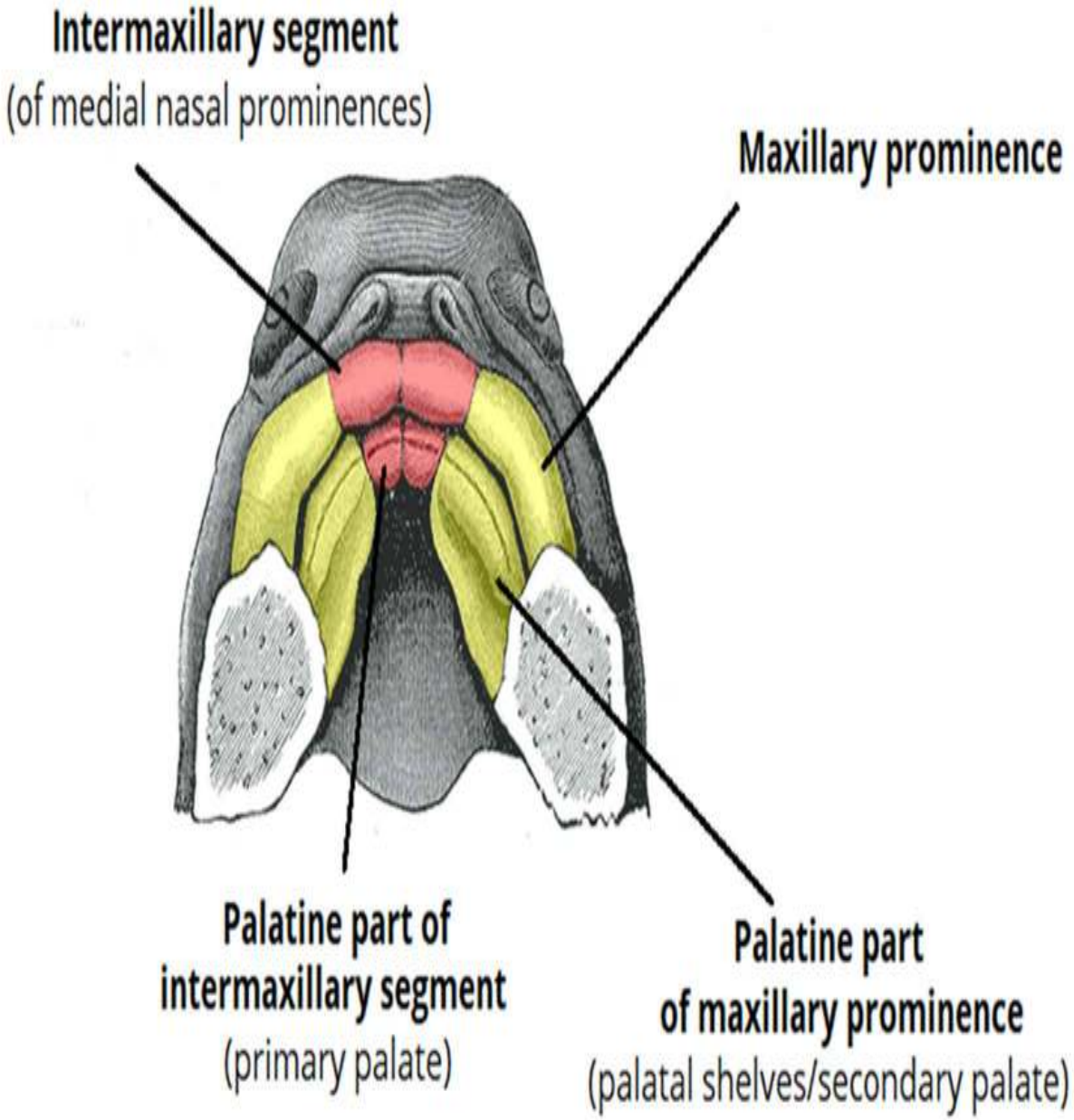
Intermaxillary segment
(of medial nasal prominences)
Maxillary prominence
Palatine part of
intermaxillary segment
(primary palate)
Palatine part
of maxillary prominence
(palatal shelves/secondary palate)

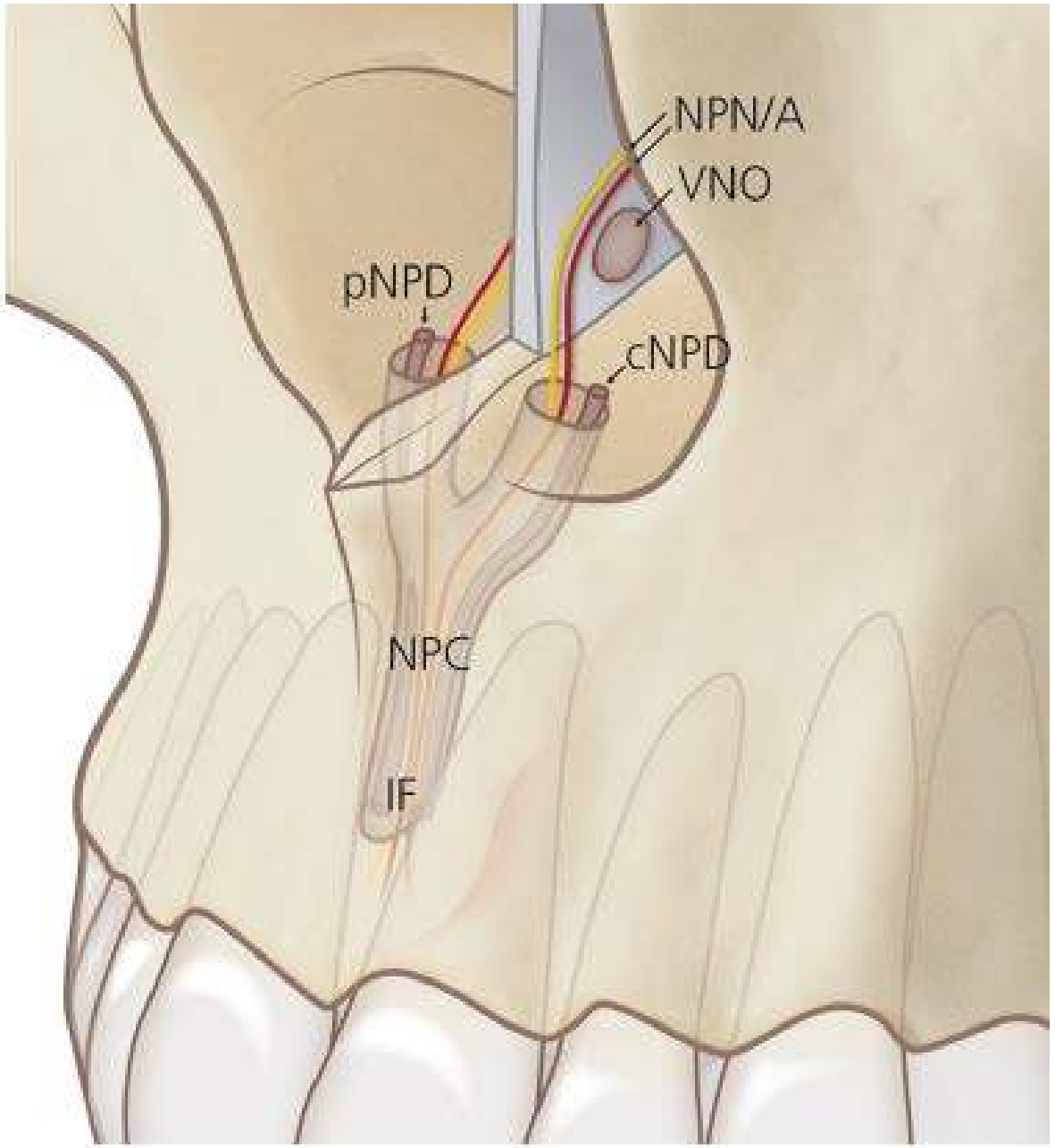
NPN/A
VNO
pNPD
cNPD
NPC
IF

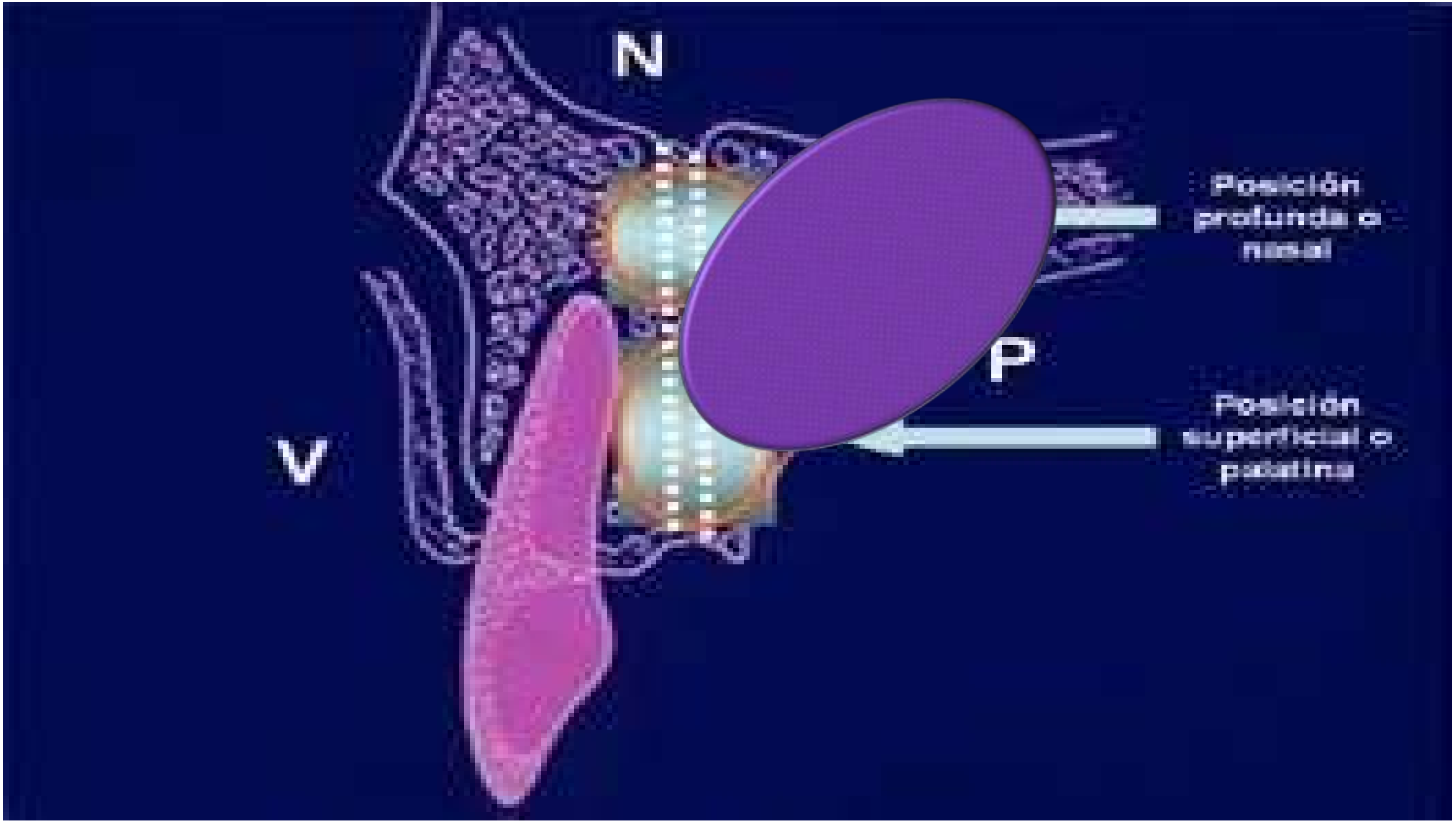
N
P
V
Posición profunda o nasal
Posición superficial o palatina

Nasopalatine duct cyst

A swelling in the incisive papilla (Black arrow) and swelling around the nasopalatine canal (White arrows)

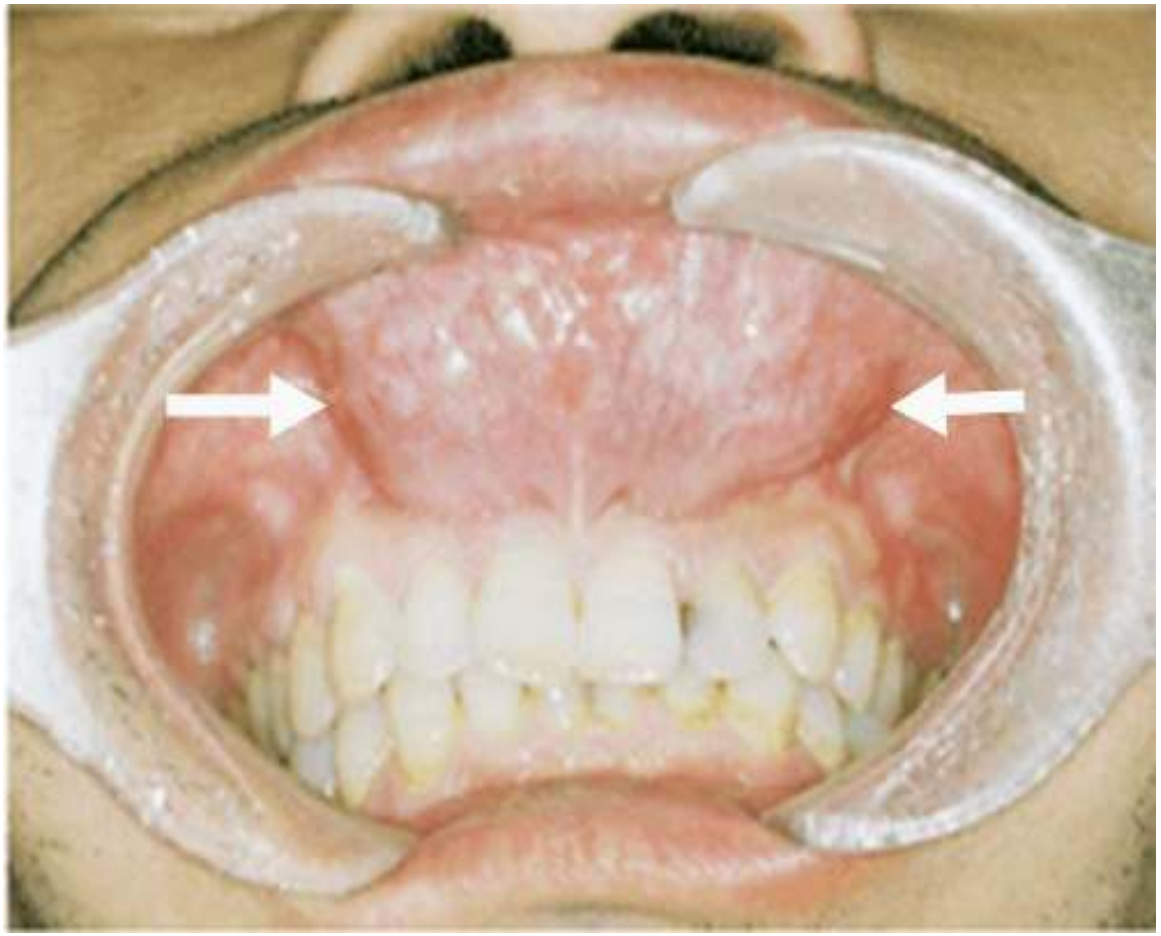

Nasopalatine duct cyst

A large cyst may produce a “through-and-through” fluctuant expansion involving the anterior palate and labial alveolar mucosa

Conventional radiographic findings for nasopalatine duct cyst

A, Panoramic radiograph. B, Occlusal radiograph.

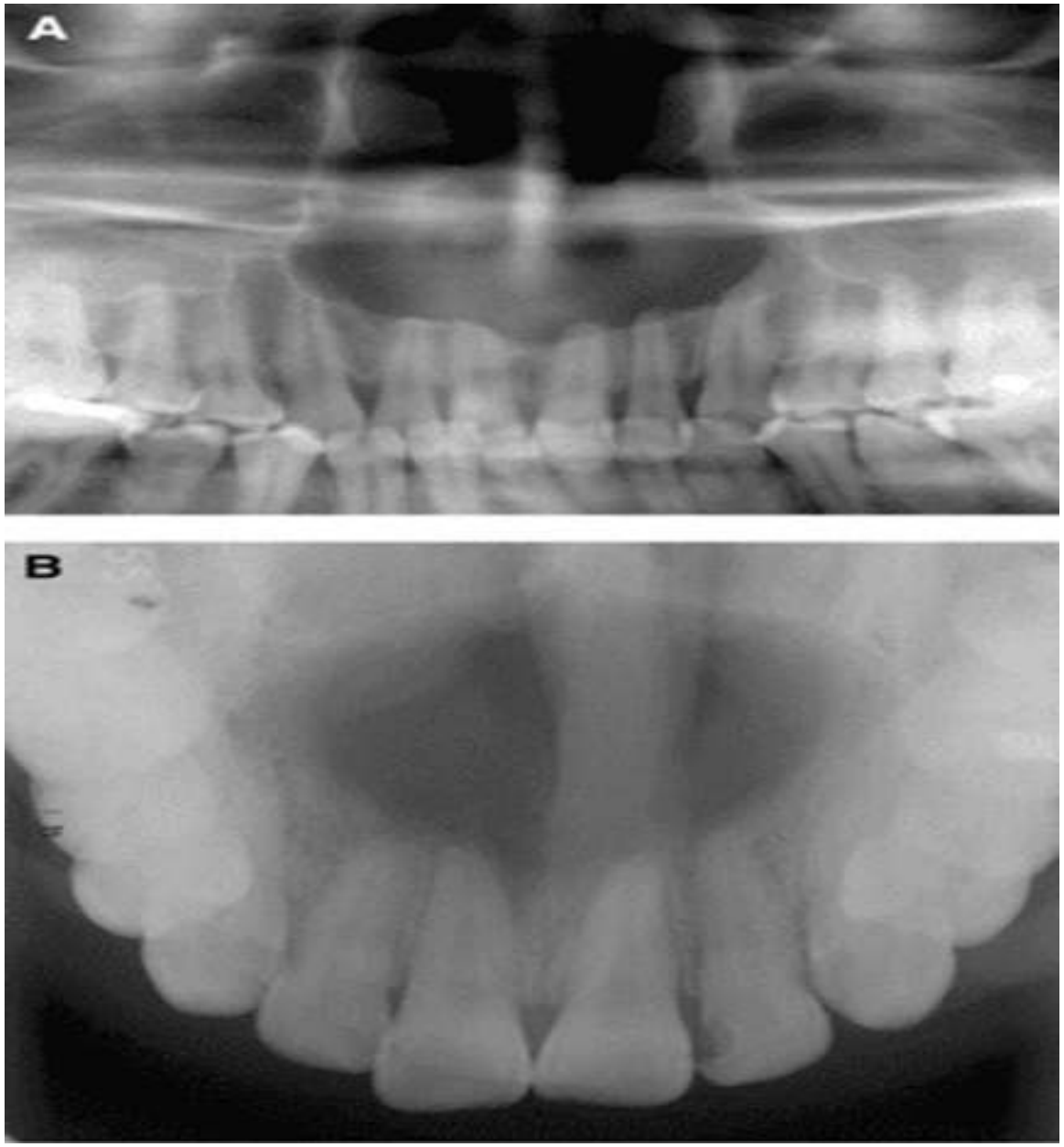

The rounded and well-defined radiolucent lesion involving the apex of central and lateral incisors. The incisors show some divergence and root resorption of central incisors are found. Producing the characteristic heart shape appearance



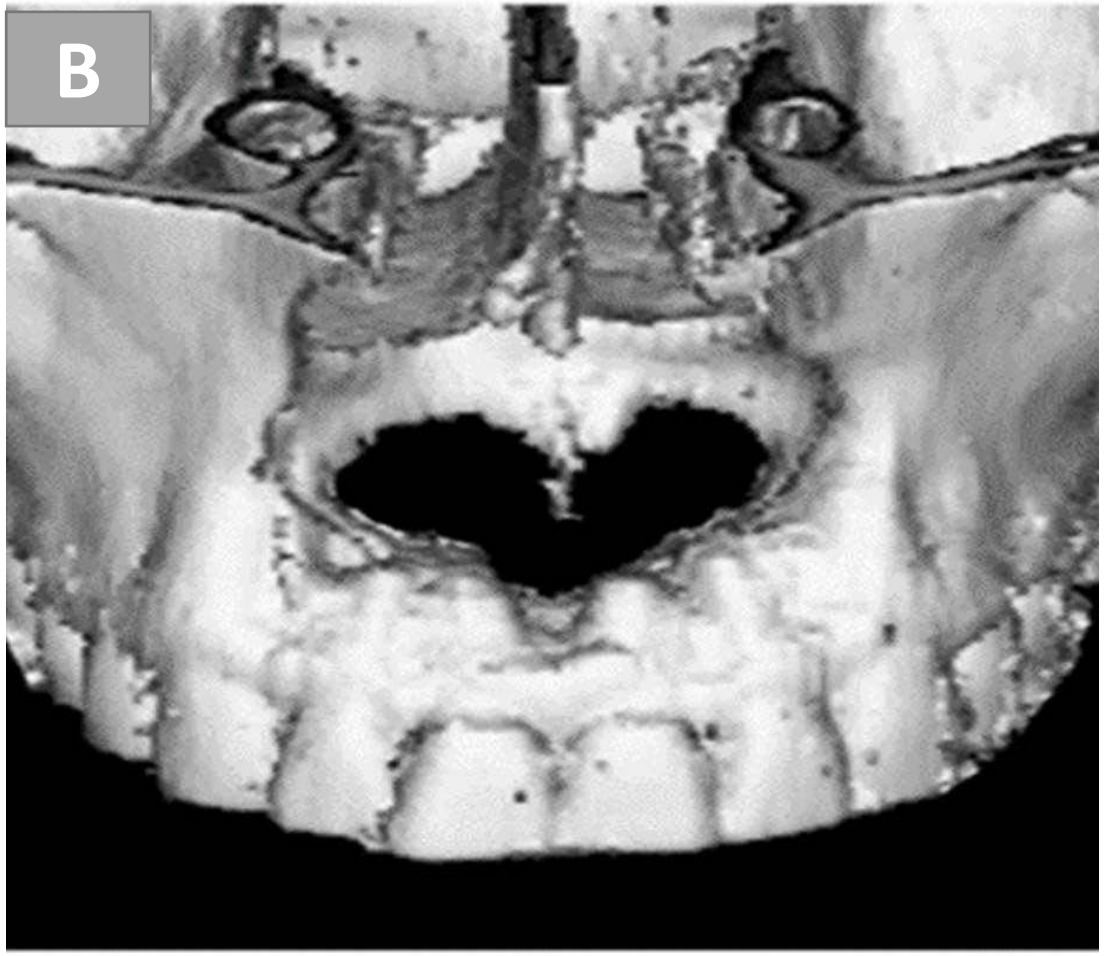

Nasopalatine duct cyst **images with the characteristic ❤ shape.**
A-MRI. B-3D CT

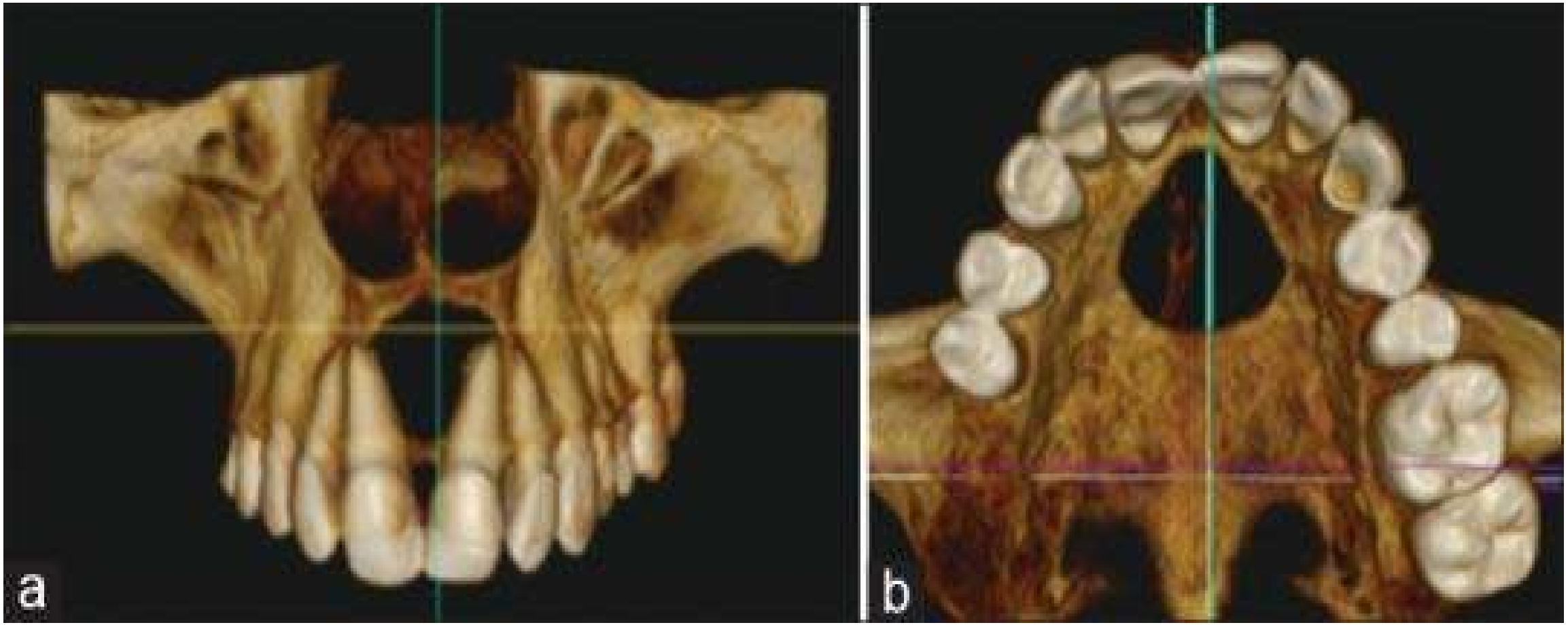

(a and b) Cone beam computed tomography images of the ***Nasopalatine duct cyst*** showing complete anterior palatine bone loss

Psuedostratified, columnar epithelium
Stratified squamous epithelium

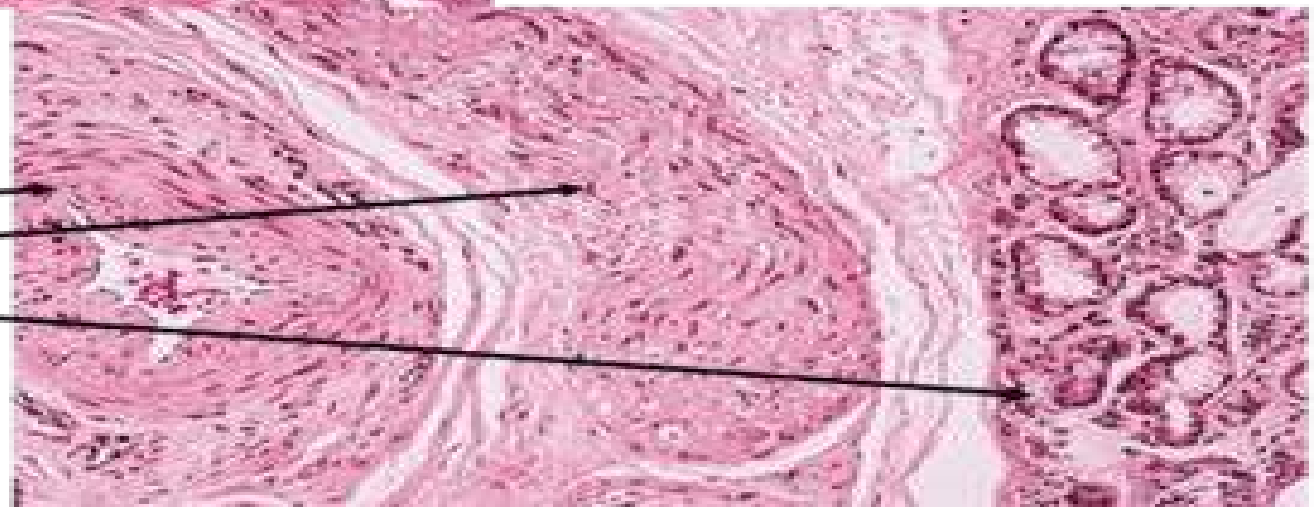
Cyst wall showing blood vessels, nerve bundles, and minor salivary glands.

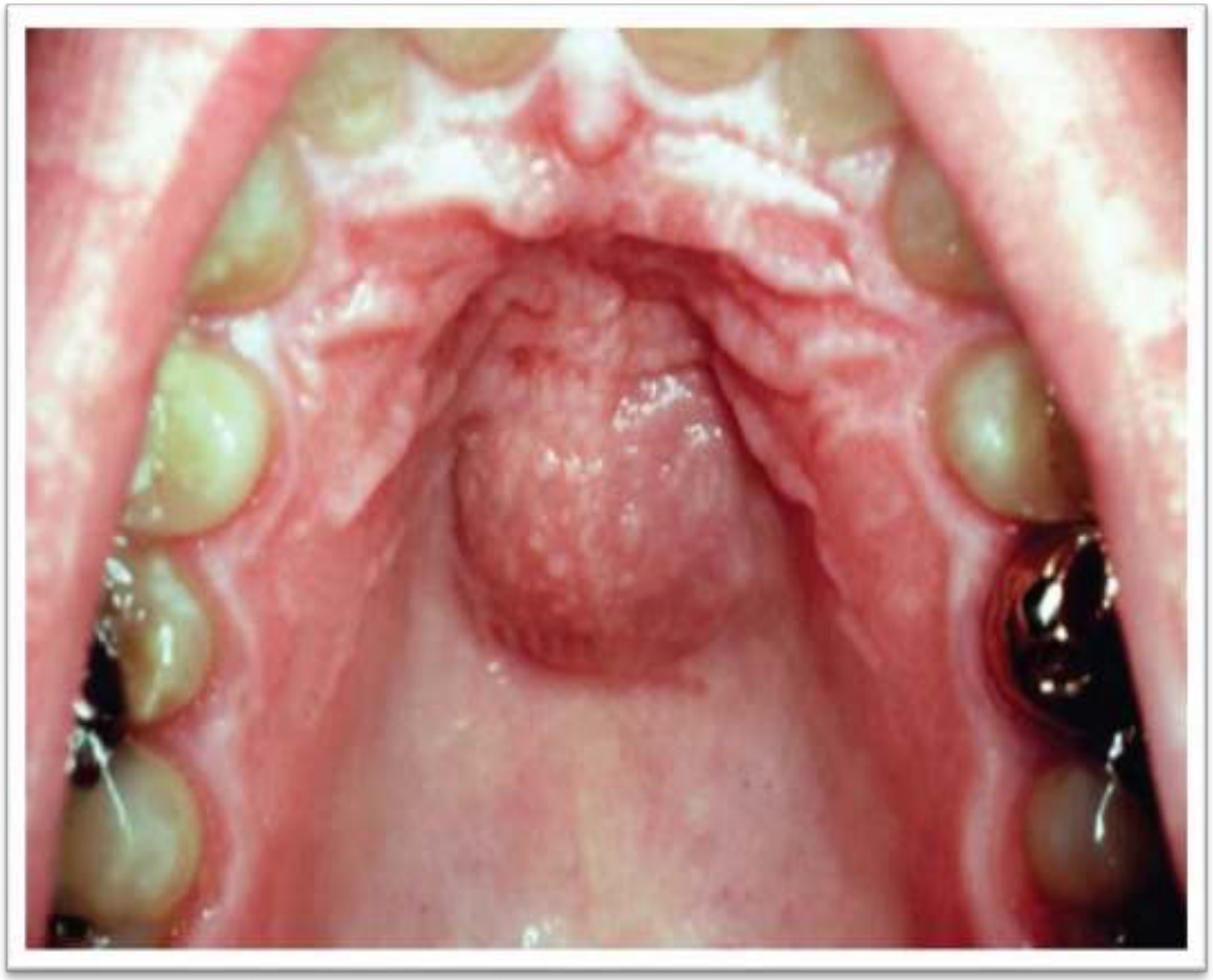

Medianpalatal (palatine) cyst

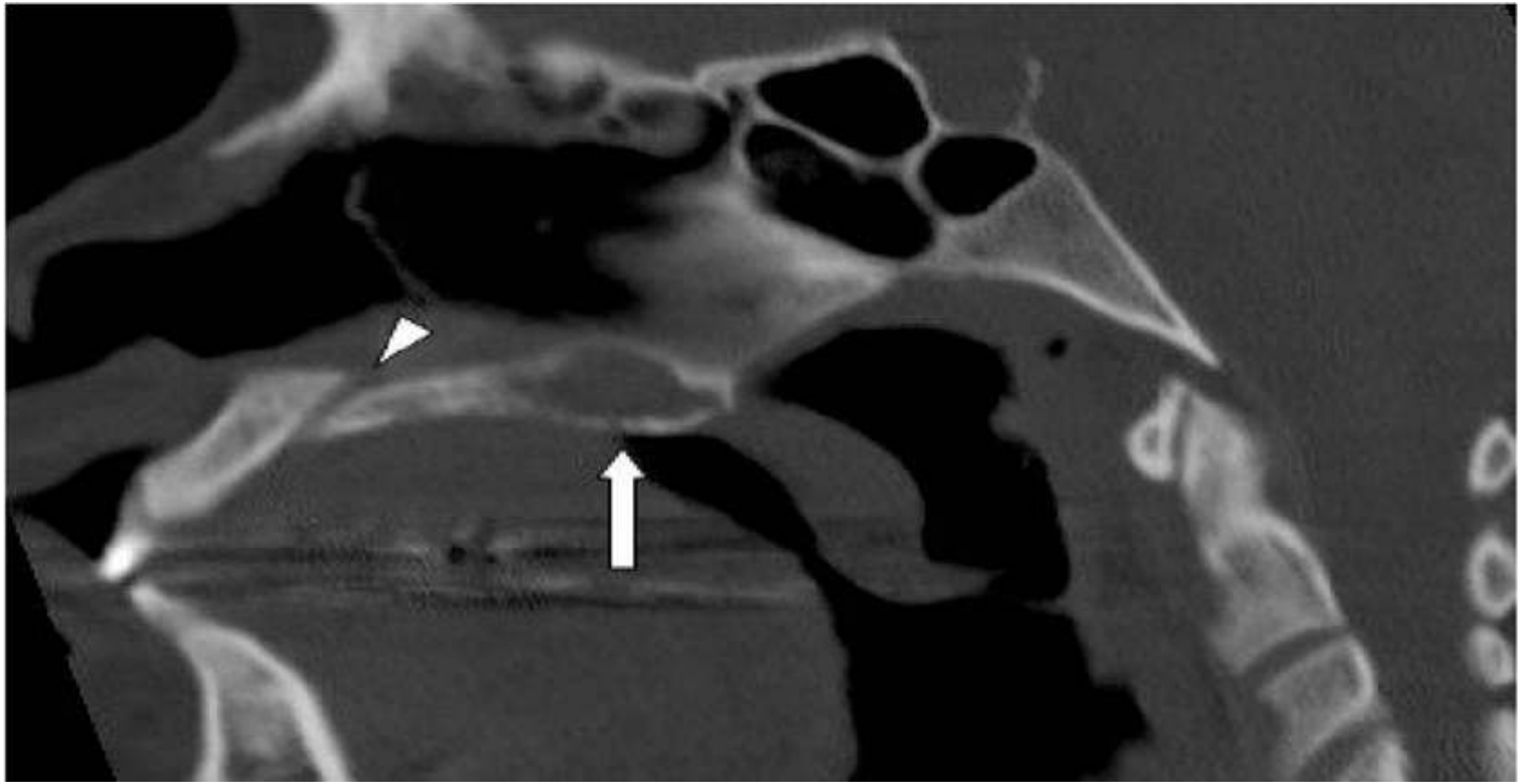

CT scan.There is no communication of the median palatine cyst (arrowhead) with the incisive canal (arrow).

Globumaxillary cyst

Swelling with different consistency in the glbulomaxillary area(between the maxillary lateral incisor and canine)

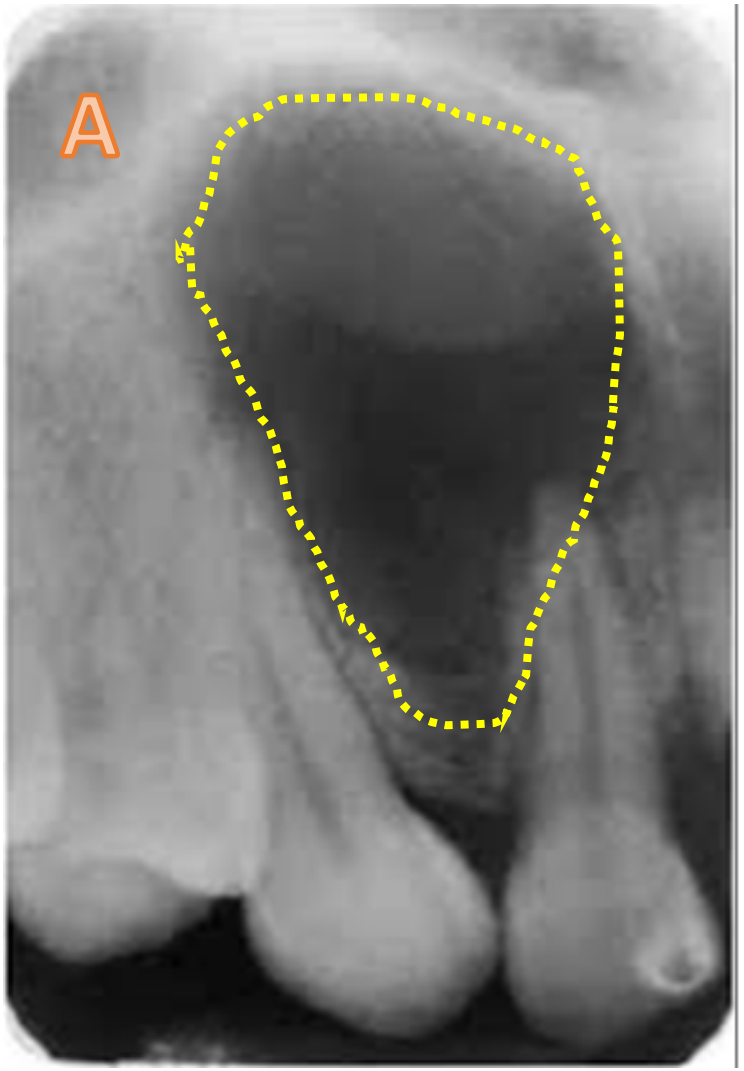

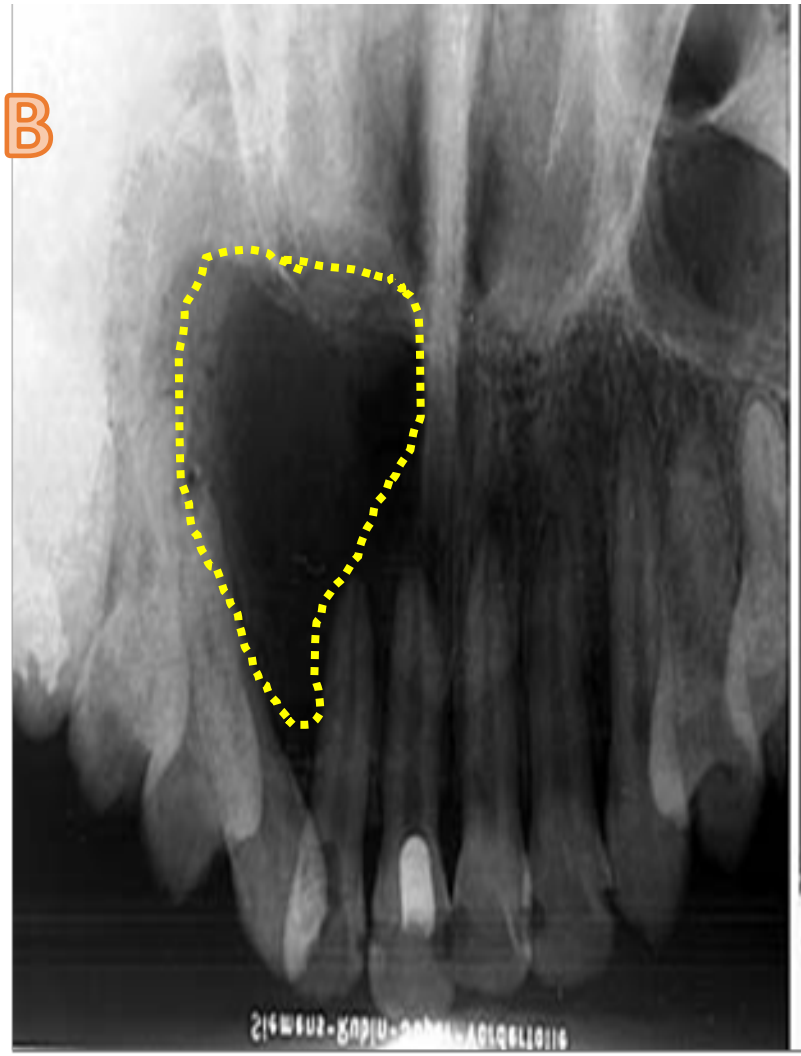

Globulomaxillary cyst with the characteristic inverted pear-shaped appearance

A-periapical B- occlusal

CT scan

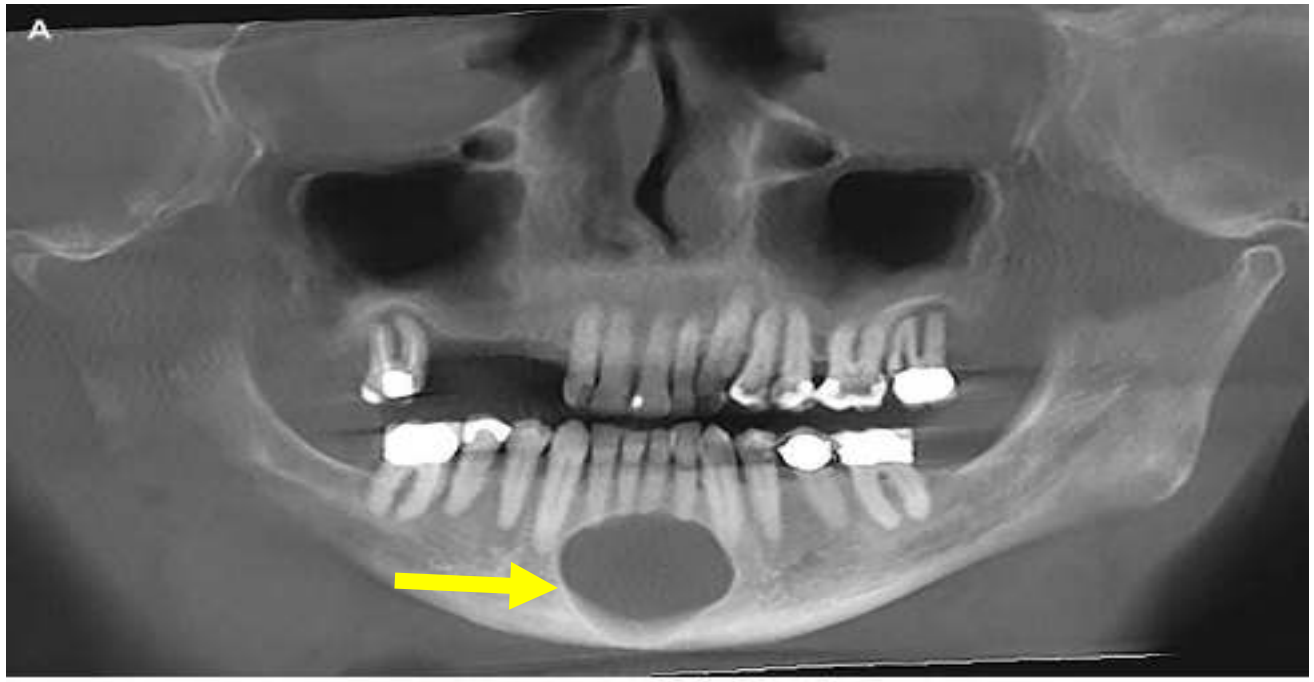

Median mandibular cyst

Because a fissural cyst in the *globulomaxillary* and *median mandibular* regions probably does not exist, the terms globulomaxillary and median mandibular cysts should no longer be used

Oral lymphoepithelial cyst

asymptomatic, mobile, well-defined nodule, firm on palpation and elevated, with a yellowish or whitish color.

Location of *lymphoepithelial cyst*:

- **posterior part of tongue**
- **floor of the mouth**
- **near the soft palate**
- **pharynx**
- **tonsilar area**
  (lymphoid tissue).

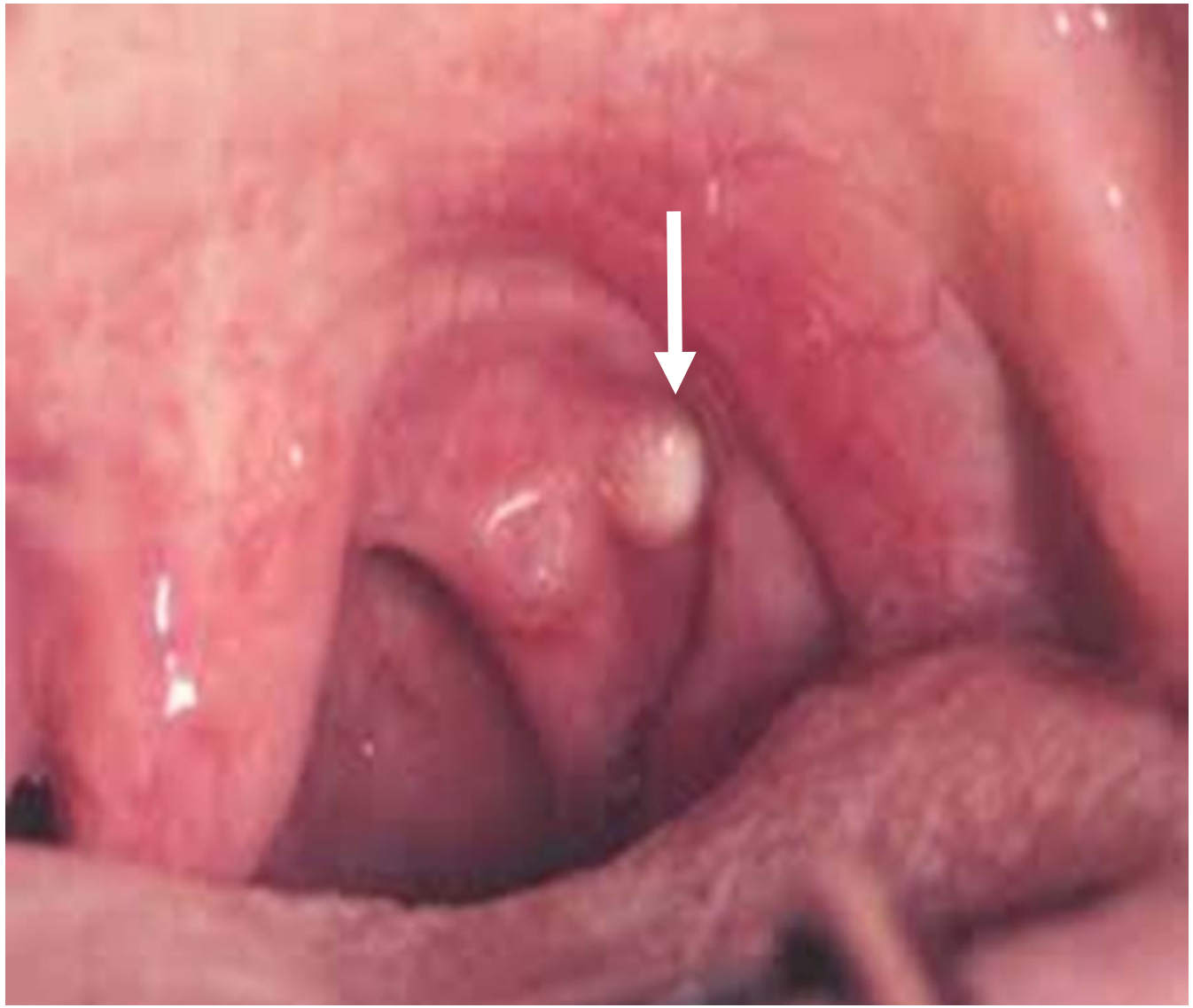

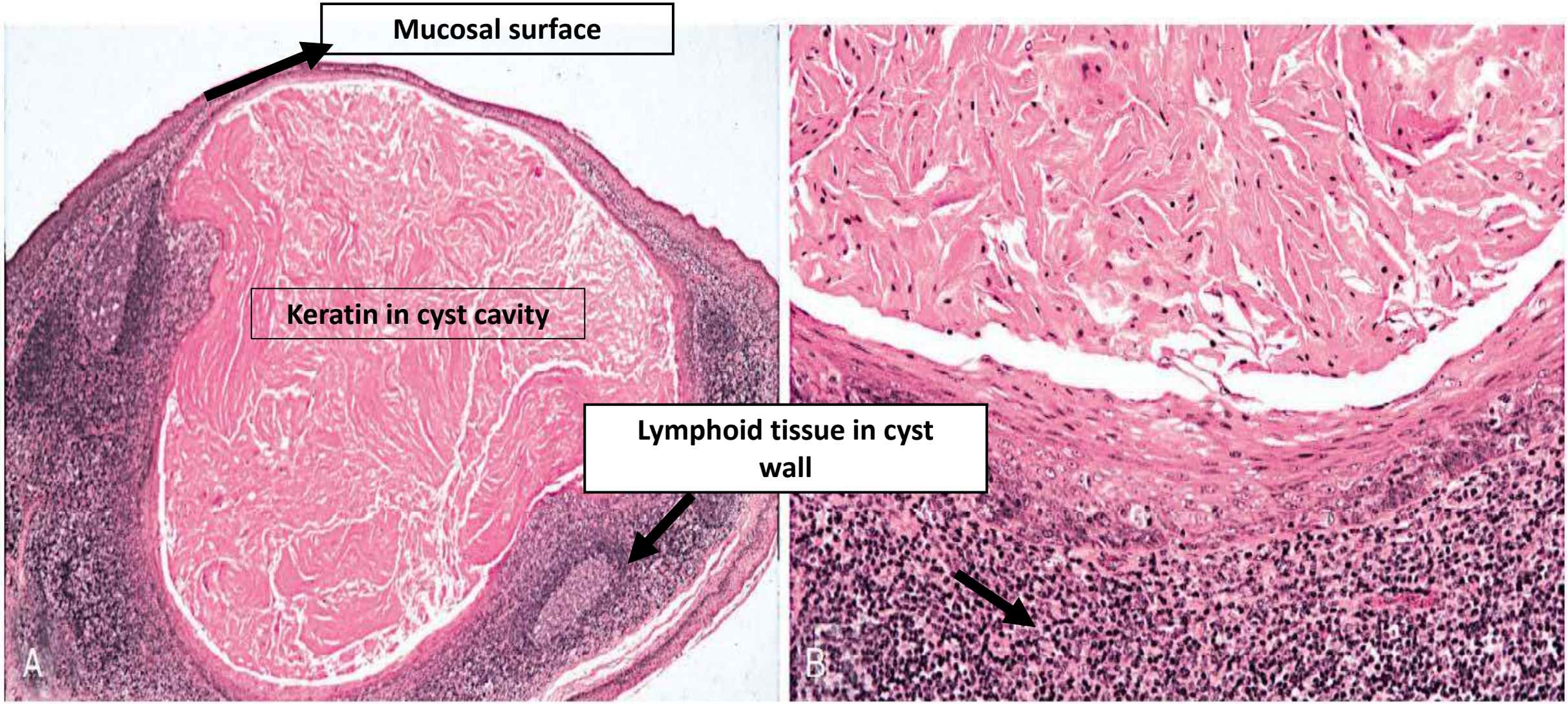

• **Fig. 1-77 Oral Lymphoepithelial Cyst. A,** Low-power view showing a keratin-filled cyst below the mucosal surface. Lymphoid tissue is present in the cyst wall. **B,** High-power view showing lymphoid tissue adjacent to the cystic lining.

Thyroglossal duct cyst

located under the hyoid bone but can be located anywhere from the suprasternal notch to the foramen cecum of the dorsal tongue.

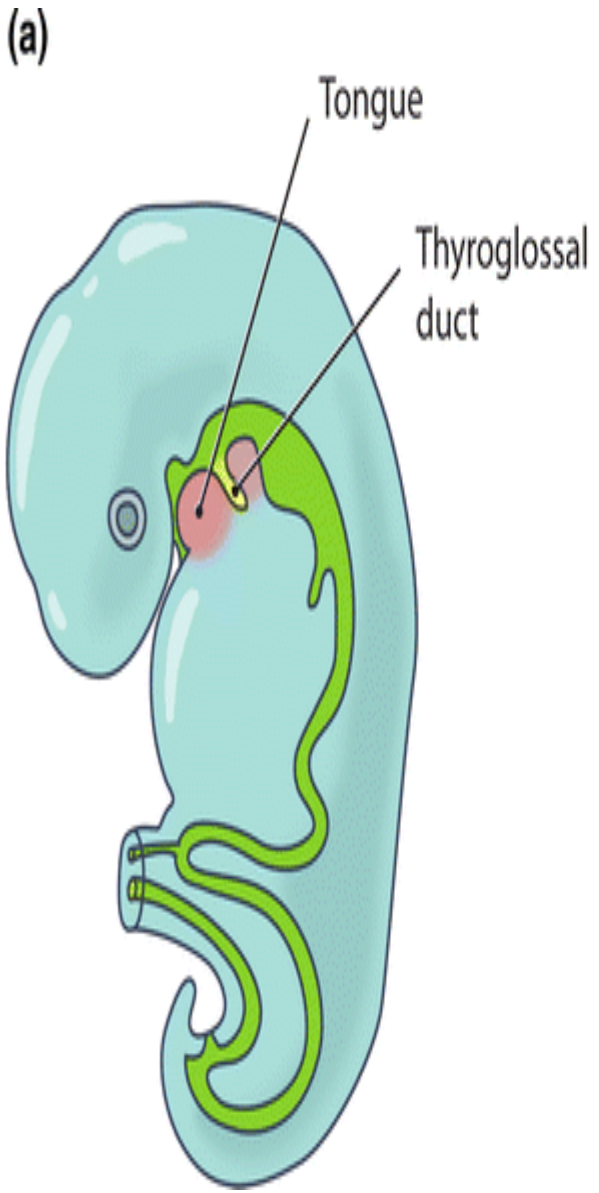
(a)
Tongue
Thyroglossal duct

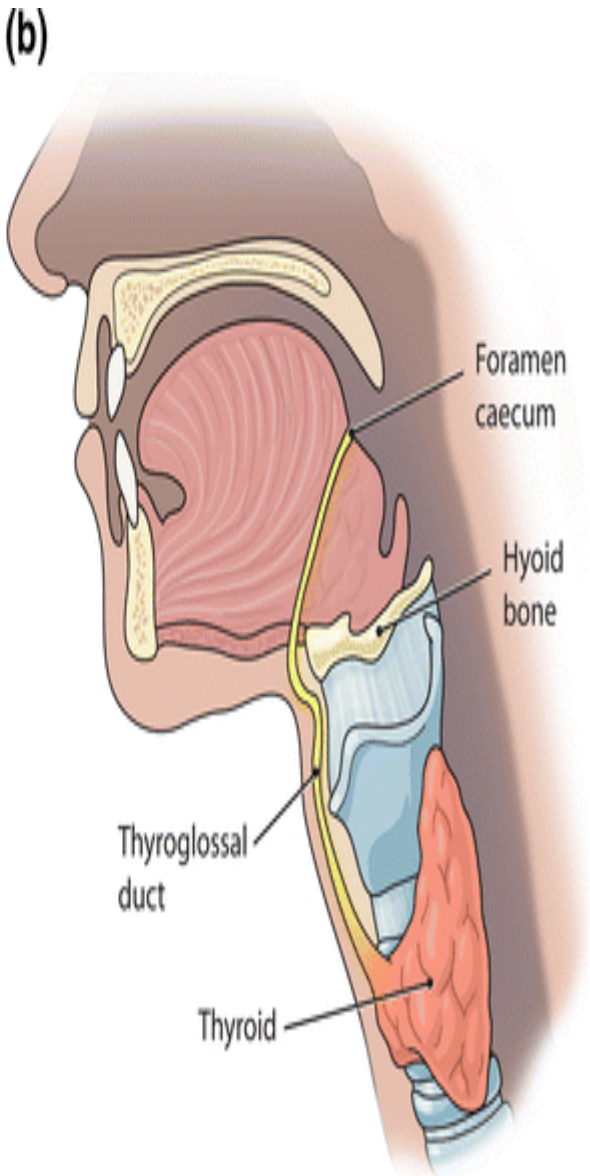
(b)
Foramen caecum
Hyoid bone
Thyroglossal duct
Thyroid

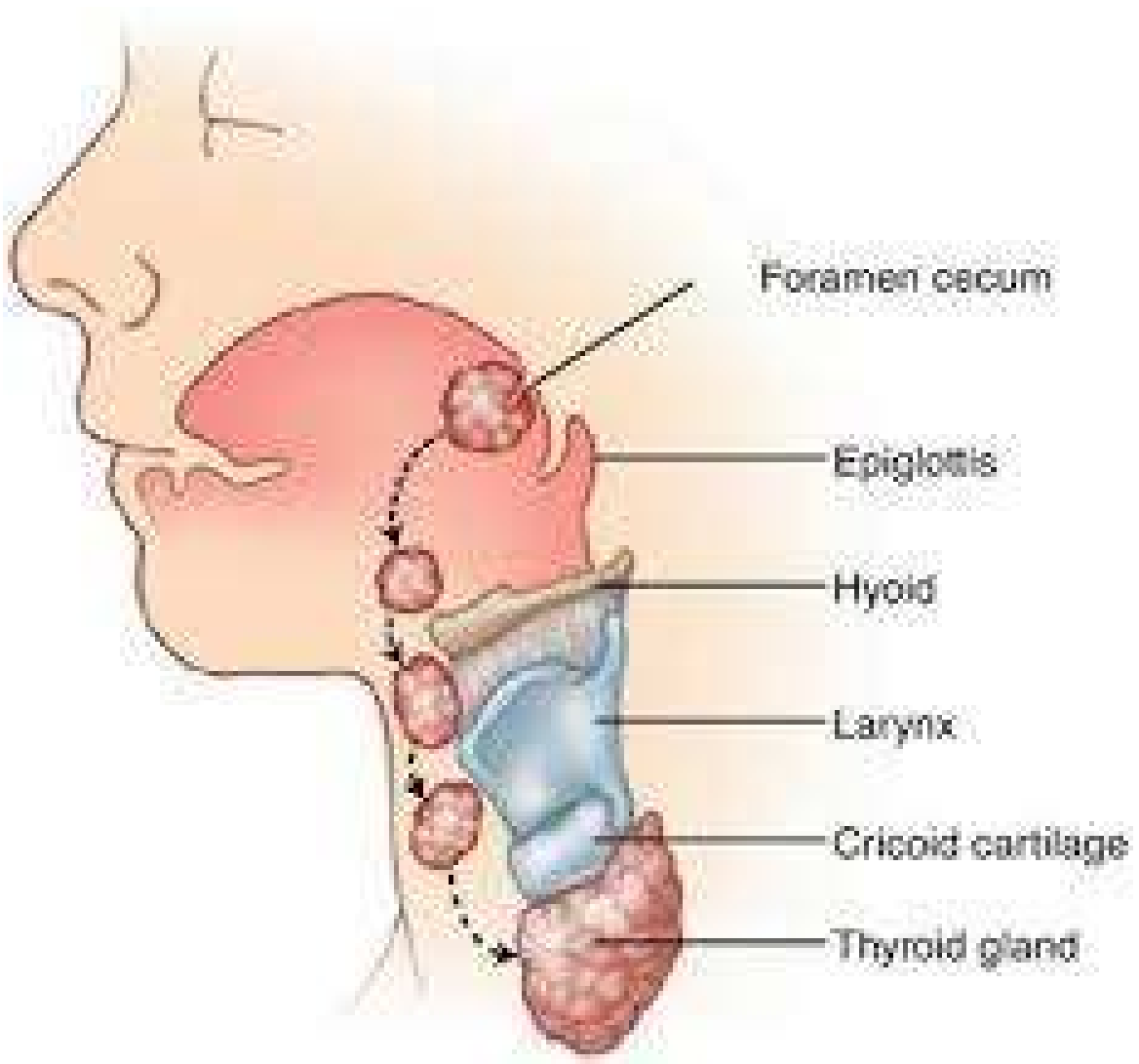
Foramen cecum
Epiglottis
Hyoid
Larynx
Cricoid cartilage
Thyroid gland

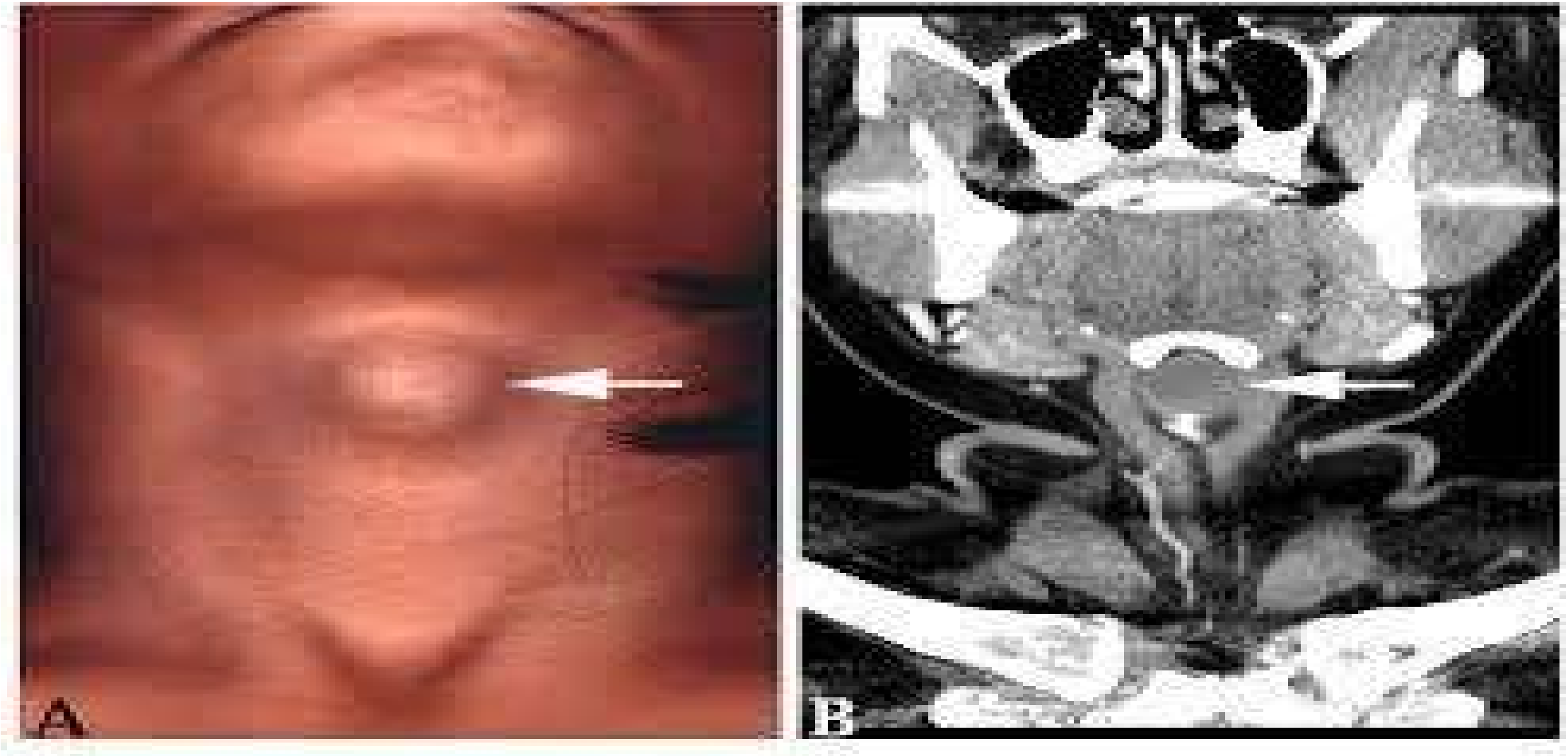

Thyroroglossal duct cyst

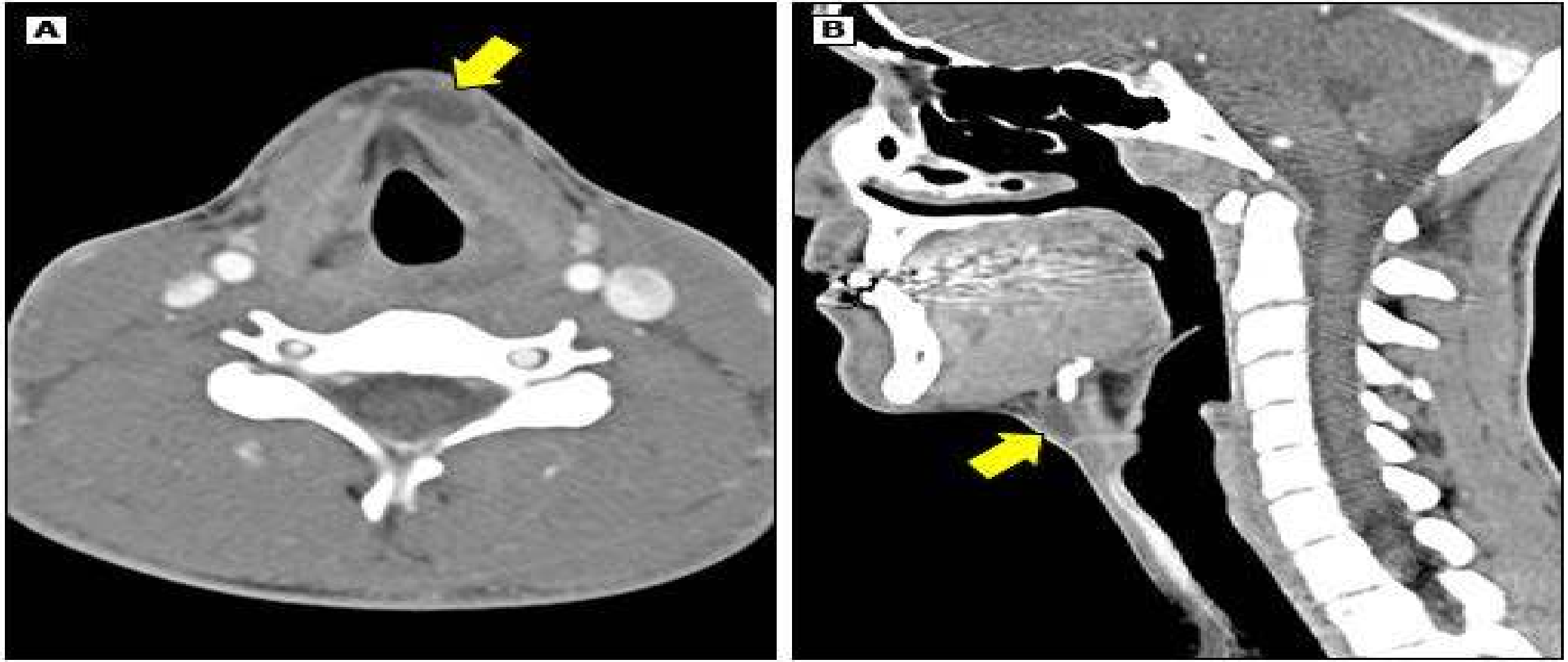

These CT scan images show a *thyroglossal duct cyst* in the (A) axial view and (B) sagittal view. The arrows indicate the cyst.

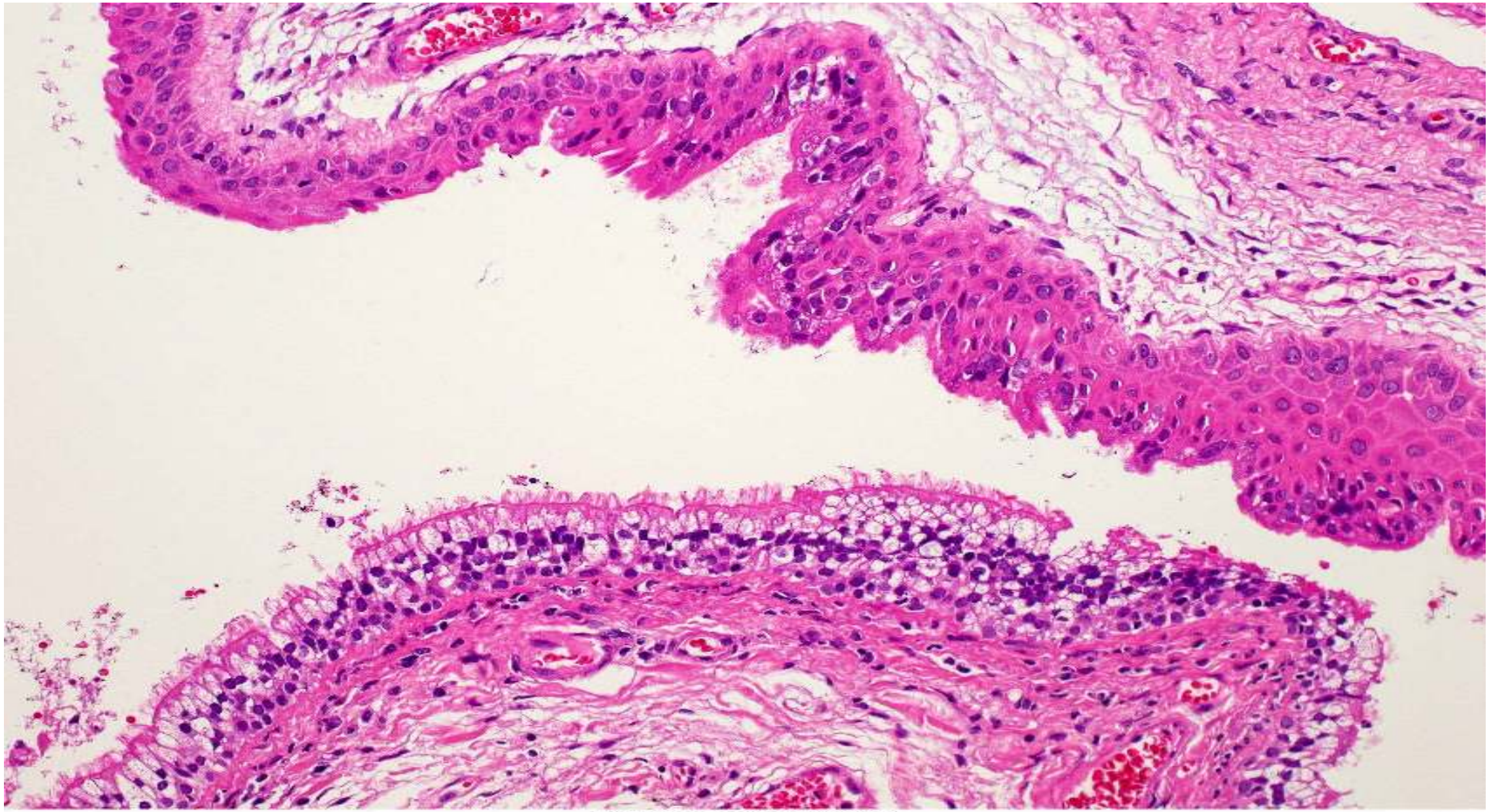

Thyroglossal duct cyst:
ciliated vs squamous epithelium (H&E, high power)

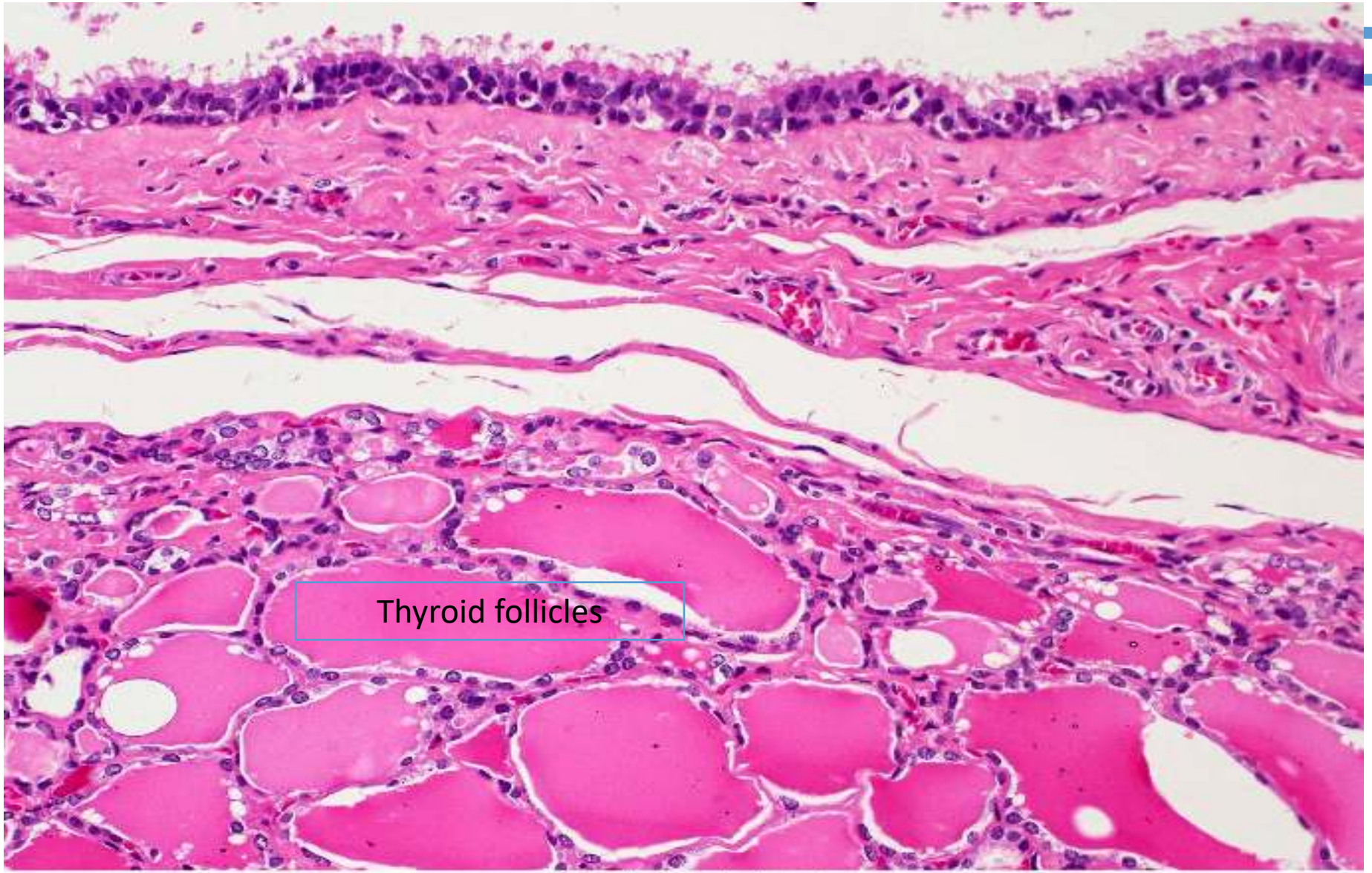

Cyst lining

Cyst wall

Thyroglossal duct cyst:
thyroid follicles under ciliated epithelium (H&E, high power)

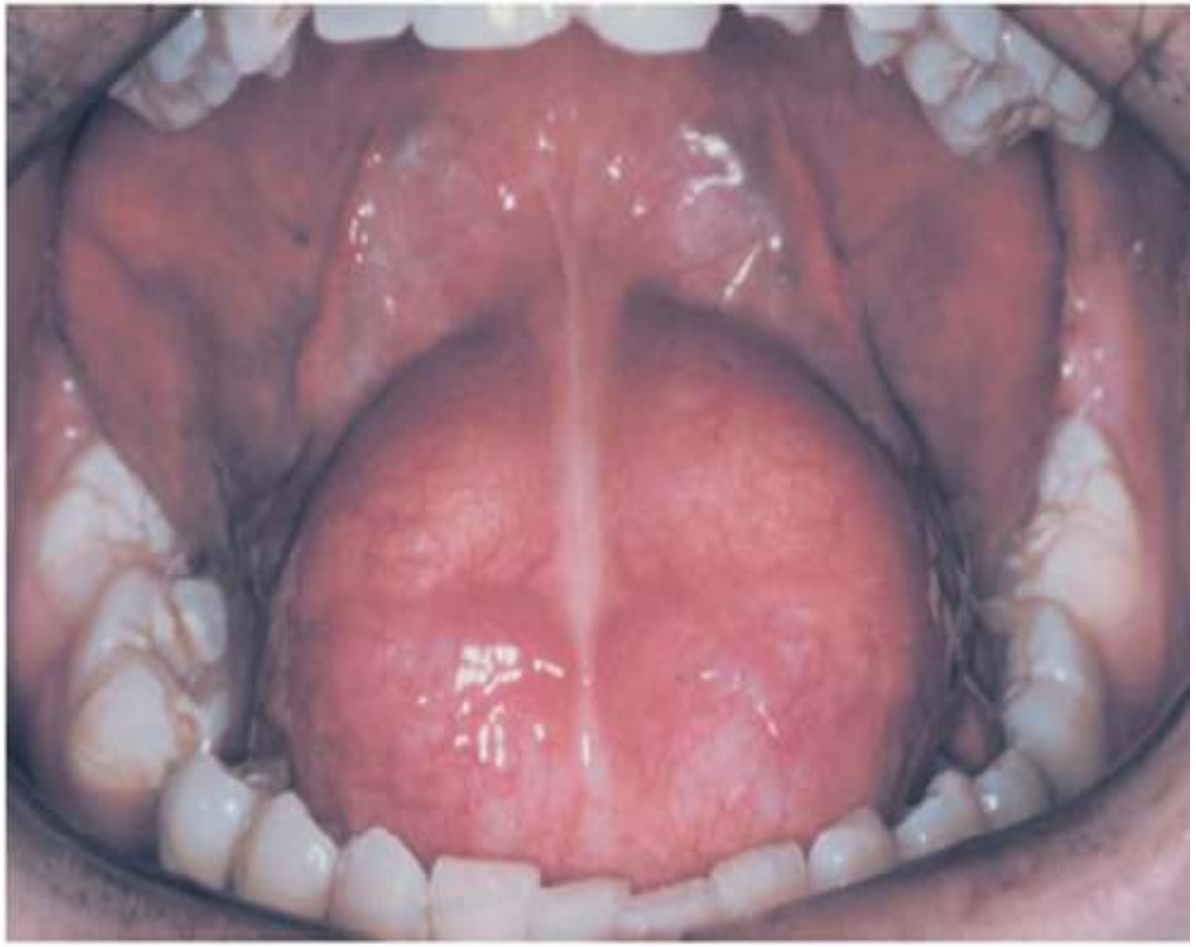

Dermoid cyst

An asymptomatic sublingual Fluctuant midline swelling in the floor of the mouth.

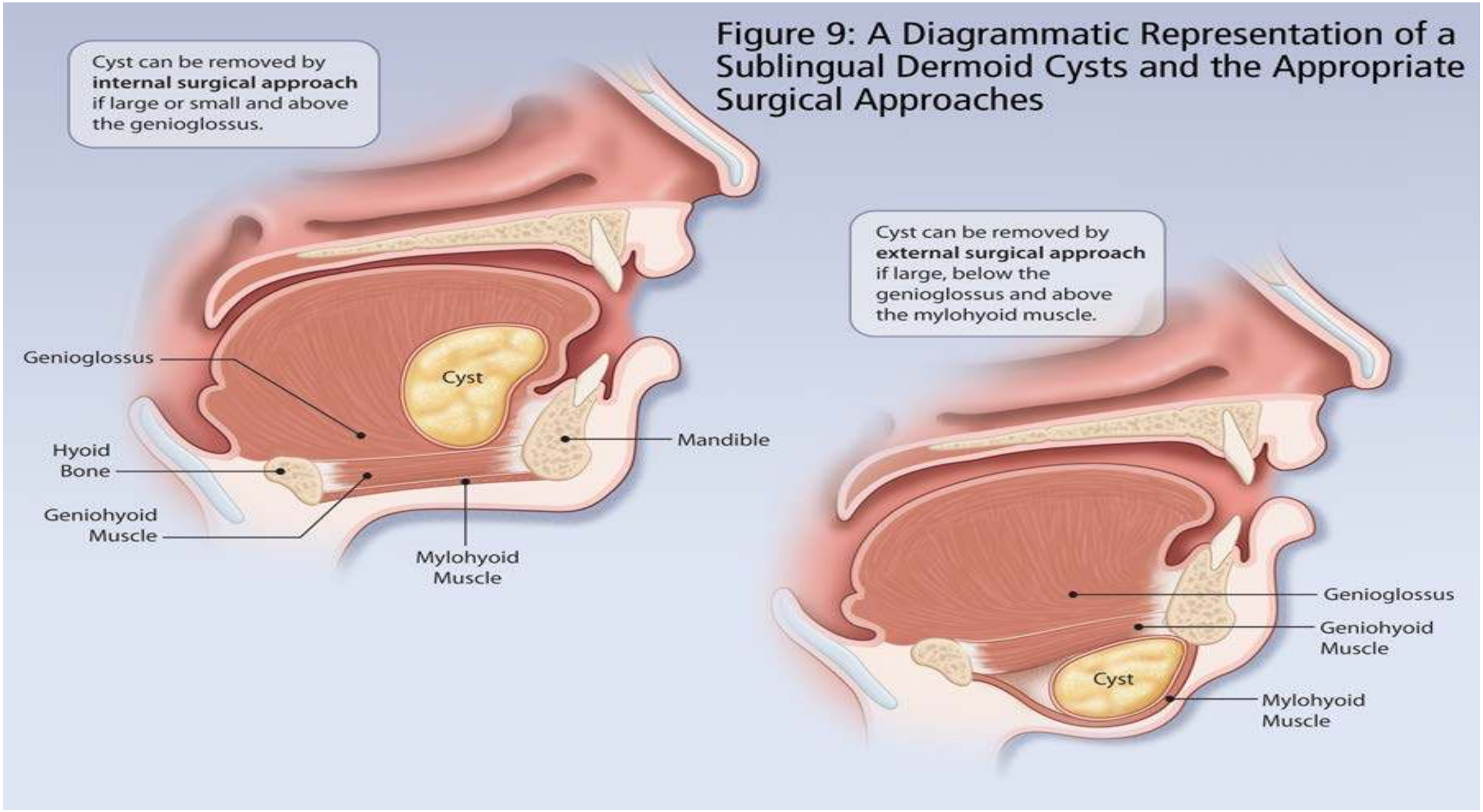
Figure 9: A Diagrammatic Representation of a Sublingual Dermoid Cysts and the Appropriate Surgical Approaches
Cyst can be removed by **internal surgical approach** if large or small and above the genioglossus.
Genioglossus
Cyst
Mandible
Hyoid Bone
Geniohyoid Muscle
Mylohyoid Muscle
Cyst can be removed by **external surgical approach** if large, below the genioglossus and above the mylohyoid muscle.
Genioglossus
Geniohyoid Muscle
Cyst
Mylohyoid Muscle

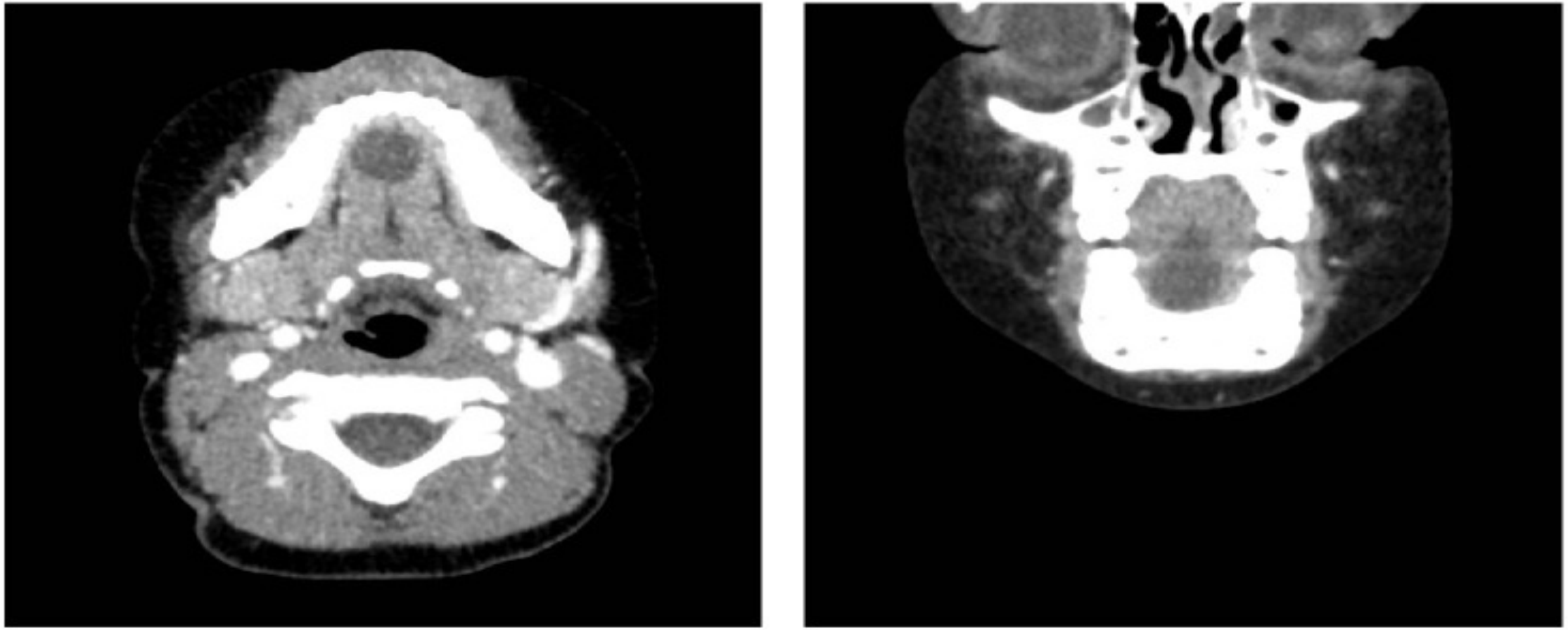

(a) (b)

Axial and coronal view of the computerized tomography scan that shows a well-marked cystic mass in the sublingual area.

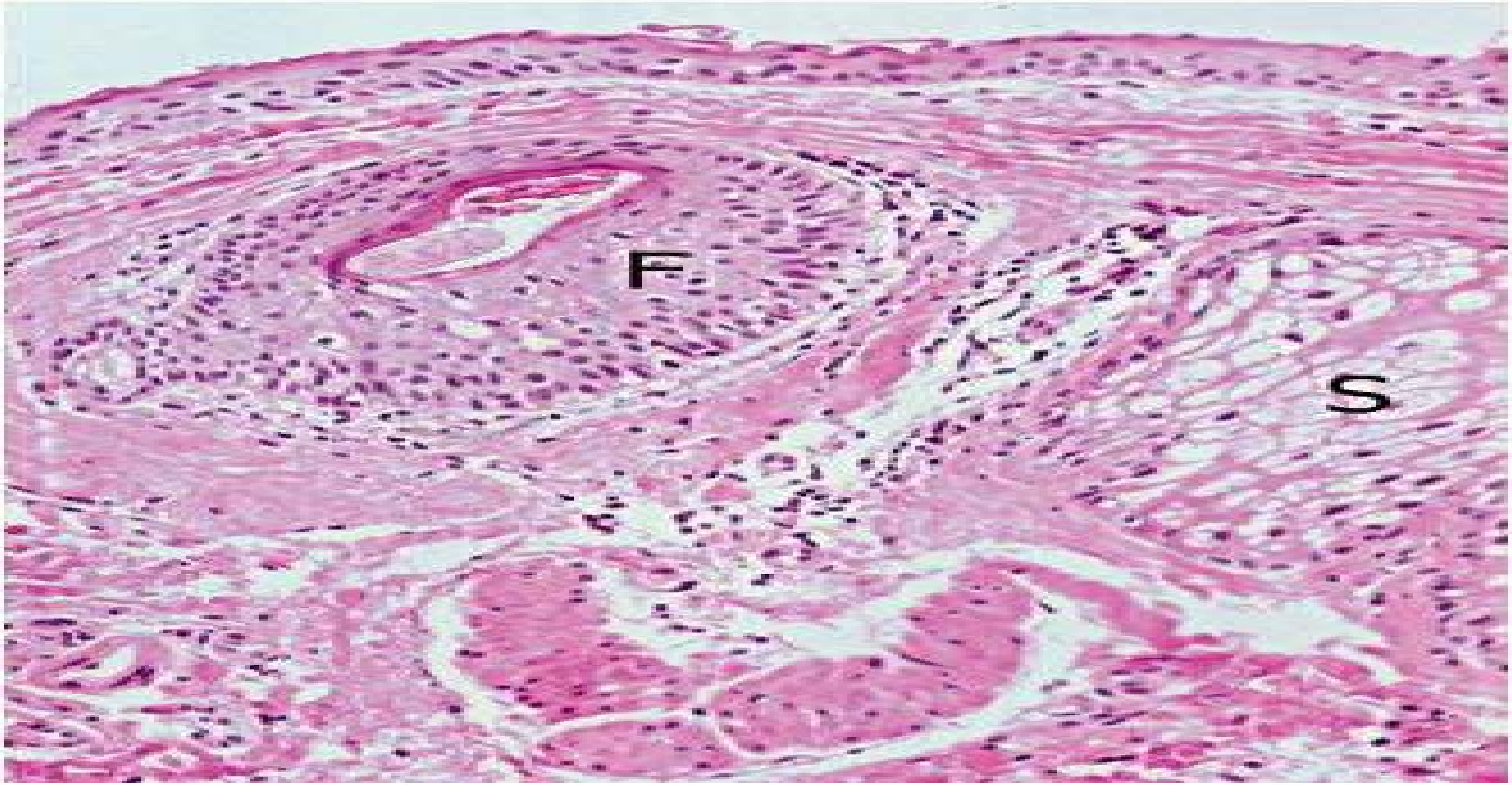

Dermoid Cyst. Squamous epithelial lining (top), with hair follicle (F), sebaceous glands (S) in the cyst wall.

Thank You!